

Soluble thrombomodulin and antibodies to bovine glomerular endothelial cells in patients with Henoch-Schönlein purpura

Mikiya Fujieda, Naobumi Oishi, Keishi Naruse, Minoru Hashizume, Koji Nishiya, Takano Kurashige, Katsumi Ito

Abstract

Aim—To evaluate the clinical significance of soluble thrombomodulin and antiendothelial cell antibodies (AECA) in children with Henoch-Schönlein purpura.

Methods—Binding of serum AECA to bovine glomerular endothelial cells was evaluated by enzyme linked immunosorbent assay, cytotoxicity against glomerular endothelial cells by spectrophotometric assay, and soluble thrombomodulin concentrations by sandwich enzyme immunoassay.

Results—IgA AECA were detected in seven of 15 patients with Henoch-Schönlein purpura and nephritis, but were not detected in patients without nephritis or in controls. Patients with Henoch-Schönlein nephritis had raised titres of IgA AECA and serum thrombomodulin; severe proteinuria and renal histological changes were associated with raised titres of IgA AECA and raised serum thrombomodulin. No subjects had complement dependent cytotoxicity against glomerular endothelial cells.

Conclusions—High titres of IgA AECA and raised serum thrombomodulin may be clinically useful markers of renal involvement in patients with Henoch-Schönlein purpura.

(Arch Dis Child 1998;78:240-244)

Keywords: antiendothelial cell antibody; Henoch-Schönlein purpura; nephritis; thrombomodulin

Henoch-Schönlein purpura is a common childhood vasculitic disorder of unknown aetiology. Henoch-Schönlein purpura and the accompanying nephritis (Henoch-Schönlein nephritis) are characterised by the deposition of IgA in the skin and the mesangium of the glomeruli. Endothelial cells may be actively involved in the immune processes that lead to glomerular injury in patients with Henoch-Schönlein nephritis.

Antiendothelial cell antibodies (AECA) have been detected in patients with such vasculitic disorders as systemic lupus erythematosus,¹⁻³ HLA matched graft rejection,⁴ haemolytic uraemic syndrome,⁵ Wegener's granulomatosis and microscopic polyarteritis,⁶ and Kawasaki disease.^{7,8} AECA appear to be correlated with the clinical severity of these diseases, suggesting a possible pathogenic role in the induction of the vasculitic process.

Thrombomodulin is a thrombin receptor present on the surface of the endothelial cells of arteries, veins, capillaries, lymphatics, platelets, and placental syncytiotrophoblast cells.^{9,10} Soluble thrombomodulin is reportedly derived from injured or inflamed endothelial cells.^{11,12} An increase in serum or plasma thrombomodulin in patients with disseminated intravascular coagulation,¹³ systemic lupus erythematosus,¹⁴ Kawasaki disease,¹⁵ and diabetic angiopathy¹⁶ has been recognised and is thought to indicate damage to the endothelial cells.

In this study our aim was to evaluate the clinical significance of soluble thrombomodulin concentrations and titres of AECA to bovine glomerular endothelial cells in children with Henoch-Schönlein purpura. The presence of AECA was determined using a cellular enzyme linked immunosorbent assay (ELISA), and soluble thrombomodulin was measured using an enzyme immunoassay. The association between AECA or soluble thrombomodulin concentrations and the clinicopathological findings was also examined.

Methods

Twenty five Japanese children (14 males and 11 females; mean age 8.3 years, range 4.0 to 15.0 years) diagnosed with Henoch-Schönlein purpura. Fifteen subjects with Henoch-Schönlein purpura developed nephritis (urinary erythrocytes ≥ 10 /high power field or proteinuria > 30 mg/dl persisted over seven days) during the course of the study. Samples of serum and urine were collected from the subjects between five and 14 days after the onset of symptoms such as purpura, abdominal pain, gastrointestinal bleeding, and arthralgia. Renal biopsy was performed between 14 and 30 days after the onset of haematuria or proteinuria in patients with nephritis to confirm damage to renal tissue for clinical purposes.

The diagnosis of Henoch-Schönlein nephritis was based on the immunofluorescent detection of marked deposits of IgA on the mesangium in renal biopsy specimens. Renal function was normal in patients at sample collection (creatinine clearance ≥ 70 ml/min/1.73 m²). Samples were also obtained from 10 febrile children (five males and five females; mean age 5.0 years, range 0.5 to 13.0 years). Four were diagnosed with pneumonia, three with otitis media, and three with infectious mononucleosis. Control samples were also obtained from 20 afebrile children (10 males

Kochi Medical School,
Kochi, Japan:
Department of
Paediatrics

M Fujieda
N Oishi
K Naruse
M Hashizume
T Kurashige

Second Department of
Medicine
K Nishiya

Department of
Paediatric Nephrology,
Kidney Centre, Tokyo
Women's Medical
College, Tokyo, Japan
K Ito

Correspondence to
Dr Mikiya Fujieda,
Department of Paediatrics,
Kochi Medical School,
Kohasu, Oko-cho, Nankoku,
Kochi 783, Japan.

Accepted 25 September
1997

and 10 females; mean age 6.5 years, range 2.0 to 14.0 years). Samples were stored at -80°C until assay. Informed consent was obtained from the parents and the children who were old enough to give consent.

ASSAY METHODS

Endothelial cell culture

Glomerular endothelial cells were cultured from adult bovine kidney as described previously,¹⁷ and cultivated in RPMI 1640 (Flow Laboratories) supplemented with 5% fetal calf serum, 5 $\mu\text{g}/\text{ml}$ of insulin, 2 ng/ml of acidic fibroblast growth factor, and 5 U/ml of heparin sodium. Cells were transferred to gelatin coated 96 well microtitre plates at a concentration of 1×10^4 cells/well for ELISA.

ELISA for antiendothelial cell antibodies

AECA were detected using the method described previously.¹⁸ In brief, glutaraldehyde fixed monolayers of glomerular endothelial cells were washed with phosphate buffered saline (PBS) and incubated with blocking buffer (1% bovine serum albumin (BSA); Sigma). After two washes with PBS, 100 μl of serum diluted 1:200 with 1% BSA-0.1 mol/l Tris-0.15 mol/l NaCl (1% BSA-TBS) was added to each well. After incubation for 18 hours at room temperature and three washes with 1% BSA-TBS, 100 μl of horseradish peroxidase conjugated goat antihuman IgG or IgA (Cappel) diluted 1:5000 with 1% BSA-TBS were added to each well. After incubation for 1 hour at room temperature and five washes, 100 μl of 3, 3', 5, 5'-tetramethyl benzidine (TMB) (Vector Laboratories) were added and absorption at 450 nm was measured. Pooled serum from two adult patients with systemic lupus erythematosus was used as a positive control for IgG AECA (optical density 1.05 and 1.31) and from two adult patients with IgA nephropathy as a positive control for IgA AECA (optical density 1.02 and 1.23). The negative control was pooled serum from seven healthy adults. The AECA titre was calculated as follows: AECA titre (%) = $100 \times (S-A)/(B-A)$, where S is the absorbance of the sample and A and B are the absorbances of the negative and positive controls, respectively. Samples were classified as positive if the AECA titre was greater than the mean +2 SD of the afebrile controls (> 32.8% for IgG AECA, > 30.6% for IgA AECA).

Cytotoxic assay

Cytotoxicity against glomerular endothelial cells in the presence of complement was determined as described previously.³ In brief, glomerular endothelial cell monolayers in 96 well microtitre plates were incubated for 6 h at 37°C with 50 μl of sera diluted 1:100 in PBS or with PBS alone, followed by incubation for 30 min at 37°C with 10 μl of human complement from fresh human AB serum. Subsequently, 10 μl of 3-(4, 5-dimethylthiazol-2-yl)-2, 5-diphenyl tetrasodium bromide (MTT) (5 mg/ml) (Research Organics) were added to each well. After incubation for 4 hours at 37°C and one wash with PBS, 100 μl of dimethylsulphoxide was

added and the absorbance at 570 nm was measured.¹⁹ The cytotoxicity against glomerular endothelial cells was calculated as follows: cytotoxicity (%) = $100 (1-S/P)$, where S is the absorbance of sample and P is the absorbance of PBS. Samples were classified as positive if the cytotoxicity was greater than the mean +2 SD of the afebrile control samples (> 36.7%).

Thrombomodulin assay

Soluble thrombomodulin was measured by a one step sandwich enzyme immunoassay using two monoclonal antibodies (Fuji Chemical Industries).¹¹ In brief, 15 μl samples of serum or urine or of an aliquot of standard soluble human thrombomodulin, and 300 μl of horseradish peroxidase conjugated purified mouse monoclonal antibody (0.5 mg/l) in 30 mmol/l sodium phosphate buffer containing 0.1% BSA, 0.1 mol/l NaCl, and 10 mmol/l EDTA were incubated for 1 hour at room temperature with a polystyrene ball which had been coated with monoclonal antibody. After the polystyrene ball was washed, TMB was added and the absorbance at 450 nm was measured. One FU/ml represents 1 ng/ml.

STATISTICAL ANALYSIS

Data are expressed as mean (SD). Wilcoxon's signed rank test was used to compare paired groups, and Wilcoxon's rank sum test to compare non-paired groups. Spearman's rank correlation test was used to evaluate relations between clinicopathological variables and IgA AECA or thrombomodulin titres. A value of $p < 0.05$ was considered statistically significant.

Results

INCIDENCE OF ANTI-ENDOROTHELIAL CELL ANTIBODIES

Only one subject was positive for IgG AECA (fig 1A). The mean IgG AECA titre did not differ significantly among the groups. IgA AECA were detected in seven of 15 patients with Henoch-Schönlein purpura and nephritis, but were not detected in patients without nephritis or in controls (fig 1B). The mean IgA AECA titre was significantly higher in the patients with nephritis (27.4(7.8)%) than in those without nephritis (20.2(4.2)%) or in febrile and afebrile controls (19.3(5.5)% and 18.2(6.2)%, respectively).

CYTOTOXICITY STUDIES

None of the patients with Henoch-Schönlein purpura showed complement dependent cytotoxicity against glomerular endothelial cells (fig 2). The mean complement dependent cytotoxicity against glomerular endothelial cells did not differ significantly among patient groups and control groups.

SOLUBLE THROMBOMODULIN

The mean serum thrombomodulin titre was significantly higher in patients with Henoch-Schönlein purpura and nephritis (4.5 (1.3) FU/ml) than in the patients without nephritis (3.2 (0.3) FU/ml) or in the febrile and afebrile controls (3.5 (1.0) and 3.4 (0.6) FU/ml, respectively) (fig 3A). Urinary excretion of

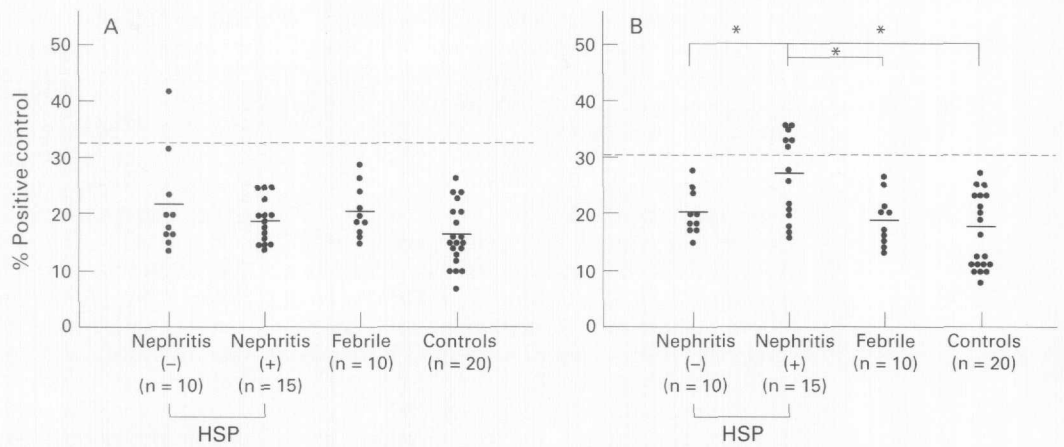


Figure 1 Effect of renal status on antibody binding activity of serum from children with Henoch-Schönlein purpura (HSP). (A) IgG antiendothelial cell antibody (AECA) binding expressed as a percentage of binding measured in pooled serum from two adult patients with systemic lupus erythematosus. (B) IgA AECA binding expressed as a percentage of binding of pooled serum from two adult patients with IgA nephropathy. The broken line indicates the upper limit of the normal range (mean +2 SD of afebrile controls). Horizontal bars represent mean values from HSP subjects and control groups. Nephritis (-) = HSP subjects without nephritis; nephritis (+) = HSP subjects with ≥ 10 urinary erythrocytes per high power field or proteinuria > 30 mg/dl; febrile = febrile control group; controls = afebrile control group. * $p < 0.01$ for the indicated comparison test.

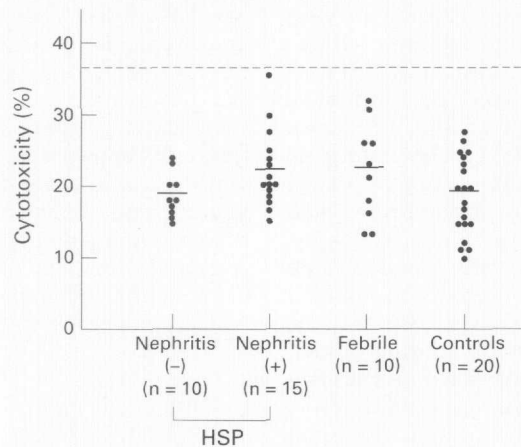


Figure 2 Effect of renal status on cytotoxicity of serum from children with Henoch-Schönlein purpura (HSP). Complement dependent cytotoxicity of serum against bovine glomerular endothelial cells was determined by absorbance of reaction mixtures containing MTT. Dashed line indicates the upper limit of the normal range (mean +2 SD of afebrile controls). Horizontal bars represent mean values from HSP subjects and control groups. Nephritis (-) = HSP subjects without nephritis; nephritis (+) = HSP subjects with ≥ 10 urinary erythrocytes per high power field or proteinuria > 30 mg/dl; febrile = febrile control group; controls = afebrile control group.

thrombomodulin in the patients with nephritis (0.94 (0.17) FU/g creatinine) and in those without nephritis (0.96 (0.26) FU/g creatinine) was slightly less than in the febrile and afebrile controls (1.10 (0.38) and 1.15 (0.42) FU/g creatinine, respectively), but the differences were not significant (fig 3B).

CLINICOPATHOLOGICAL ASSOCIATIONS

We found no correlation between the serum concentration of immunoglobulin (IgG or IgA) and IgG or IgA AECA titres in the subjects with Henoch-Schönlein purpura. However, there was a significant correlation ($r = 0.617$, $n = 25$, $p < 0.01$) between IgA AECA titres and serum thrombomodulin titres in the subjects with Henoch-Schönlein purpura (data not shown). Among the patients with Henoch-Schönlein purpura and nephritis, those with proteinuria exceeding 1 g/day had a signifi-

cantly higher titre of IgA AECA than the patients with less proteinuria, at 32.6(4.9)% *v* 19.7(3.6)% (table 1). All seven patients positive for IgA AECA had proteinuria exceeding 1 g/day. In addition, subjects with diffuse mesangial proliferative glomerulonephritis or $> 10\%$ cellular crescents had significantly higher titres of IgA AECA (30.6(6.9)% and 30.8(6.2)%, respectively) than the patients with milder disease (21.0(5.6)% and 22.3(7.6)%, respectively). All seven patients positive for IgA AECA had diffuse mesangial proliferative glomerulonephritis; six of the seven patients had $\geq 10\%$ cellular crescents. Declining titres of IgA AECA were associated with decreased proteinuria; thus IgA AECA were no longer raised after proteinuria had subsided in the course of a two year follow up (data not shown). Only one of the seven IgA AECA positive subjects with nephritis had persistent proteinuria and was continuously positive for IgA AECA (31.2% at two years after onset). However, this patient's renal function remained stable during the two year follow up period.

We found higher serum titres of thrombomodulin in patients with Henoch-Schönlein purpura and nephritis when proteinuria exceeded 1g/day (5.0 (1.5) FU/ml) or when there were $\geq 10\%$ cellular crescents (5.0 (1.5) FU/ml) than in the children with less severe nephritis (3.8 (0.6) and 3.9 (0.8) FU/ml, respectively) (table 1). The serum thrombomodulin titre decreased to within the normal range with the disappearance of symptoms such as purpura, abdominal pain, gastrointestinal bleeding, and arthralgia, and concomitant with decreases in the severity of proteinuria (data not shown). The one subject persistently positive for proteinuria and IgA AECA mentioned above had a slightly raised serum thrombomodulin (4.2 FU/ml) at two years after disease onset.

Discussion

The AECA obtained from patients with vasculitic disorders^{3,20} or Kawasaki disease^{7,8} shows

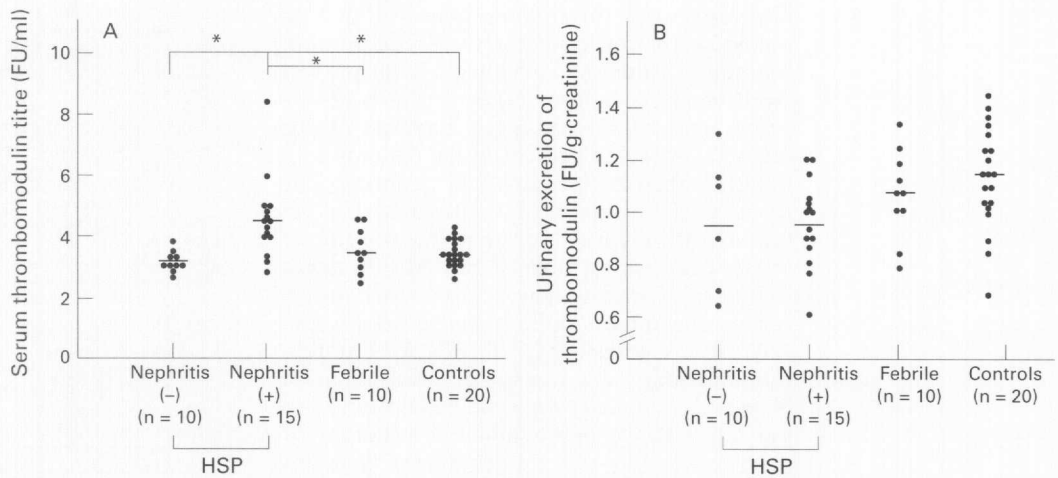


Figure 3 Effect of renal status on serum and urinary thrombomodulin in children with Henoch-Schönlein purpura (HSP). Concentrations of thrombomodulin in (A) serum and (B) urine were measured by sandwich enzyme immunoassay. Horizontal bars represent mean values from HSP subjects and control groups. Nephritis (-) = HSP subjects without nephritis; nephritis (+) = HSP subjects with ≥ 10 urinary erythrocytes per high power field or proteinuria $> 30\text{mg/dl}$; febrile = febrile control group; controls = afebrile control group. * $p < 0.01$ for the indicated comparison test.

antibody dependent cell cytotoxicity or complement dependent cytotoxicity against human umbilical vein endothelial cells in vitro. In a guinea pig model of experimental nephritis, immunisation with an endothelial cell membrane preparation caused mesangial proliferation with positive IgG and C3 staining of the peripheral capillary loop and mesangium, and resulted in a high titre of serum AECA.²¹ These findings suggest that an AECA mediated immune mechanism can induce glomerular injury.

We previously reported that three of 18 Henoch-Schönlein purpura patients were positive for IgA AECA which react with human umbilical vein endothelial cells. All of these patients developed nephritis. However, their titres of IgA AECA to human umbilical vein endothelial cells were only slightly above the normal range.²² Preliminary data²³ indicating the presence of IgA AECA that would react with glomerular endothelial cells in Henoch-Schönlein nephritis were confirmed in the present study. Partial characterisation of some of the antigens recognised by IgA AECA

showed that the antibodies were not specific for glomerular endothelial cells.²³ Reaction with surface antigens on both glomerular endothelial cells and fibroblasts was observed, suggesting the presence of common antigens.

Patients with Henoch-Schönlein nephritis with proteinuria exceeding 1 g/day or active renal histological findings had significantly higher IgA AECA titres, and a decrease in IgA AECA titre was associated with clinical improvement. These findings suggest that IgA AECA that react with glomerular endothelial cells may be a marker for the presence and activity of Henoch-Schönlein nephritis. Moreover, the binding of IgA AECA to endothelial cells may cause glomerular capillary endothelial cell damage through migration of inflammatory cells. However, cytotoxicity—such as complement dependent cytotoxicity or antibody dependent cell cytotoxicity (data not shown)—against glomerular endothelial cells was not observed, suggesting that factors other than the production and binding of IgA AECA contribute to renal injury. Alternatively, endothelial cell damage of unidentified cause may expose endothelial antigen, resulting in the production and deposition of IgA AECA.

In the present study, we could not examine other markers of endothelial damage such as adhesion molecules and von Willebrand factor.^{24, 25} Söylemezoğlu *et al* recently suggested that plasma von Willebrand factor is a good marker of the severity of vasculitis in Henoch-Schönlein purpura, and intercellular adhesion molecule-1 but not E-selectin might be an additional index in some patients.²⁶ However, this report did not establish the association between these variables and renal involvement.

The increase in soluble thrombomodulin concentrations in serum or plasma is presumed to reflect endothelial cell damage.^{13-16, 27, 28} In the present study, the rise in serum thrombomodulin titre in patients with Henoch-Schönlein nephritis suggested the presence of damage to the renal arterioles, capillaries, or venules. Previous studies have suggested that the renal

Table 1 Association between clinicopathological variables and IgA AECA titres or thrombomodulin (TM) concentrations in patients with Henoch-Schönlein purpura and nephritis

| | IgA AECA titre (% positive control) | Serum TM concentration (FU/ml) |
|-----------------------|--|--------------------------------------|
| <i>Urinalysis</i> | | |
| Urine erythrocytes | | |
| <100/HPF (n=7) | 25.6 (9.1) | 4.8 (1.7) |
| ≥ 100 /HPF (n=8) | 29.0 (6.8) | 4.3 (0.9) |
| Proteinuria | | |
| <1.0 g/d (n=6) | 19.7 (3.6) ^a | 3.8 (0.6) ^d |
| ≥ 1.0 g/d (n=9) | 32.6 (4.9) ^a | 5.0 (1.5) ^d |
| <i>Histology</i> | | |
| Pattern | | |
| MGA+FGN (n=5) | 21.0 (6.9) ^b | 4.0 (0.5) |
| DPGN (n=10) | 30.6 (5.6) ^b | 4.8 (1.5) |
| Cellular crescents | | |
| <10% (n=6) | 22.3 (7.6) ^c | 3.9 (0.8) ^e |
| $\geq 10\%$ (n=9) | 30.8 (6.2) ^c | 5.0 (1.5) ^e |

DPGN = diffuse mesangial proliferative glomerulonephritis; FGN = focal glomerulonephritis; HPF = high power field; MGA = minor glomerular abnormality. Values are mean (SD).
^{aa}, ^{bb} $p < 0.01$; ^{cc}, ^{dd}, ^{ee} $p < 0.05$.

clearance of thrombomodulin influenced serum or plasma concentrations of thrombomodulin,^{16, 29} but none of patients in the present study had renal failure. It is probable that more severe and more prolonged damage to the endothelial cells is present in the patients with nephritis than in those without nephritis. The decrease in serum thrombomodulin that occurred with clinical improvement was similar to the decrease in titres of IgA AECA, and a significant correlation was observed between serum thrombomodulin concentrations and IgA AECA titres, suggesting that thrombomodulin may be a marker of the severity of glomerular capillary endothelial cell injury in patients with Henoch-Schönlein purpura.

In conclusion, our results suggest that IgA AECA that react with glomerular endothelial cells may be a useful marker of the presence and severity of Henoch-Schönlein nephritis in patients with Henoch-Schönlein purpura. Serum thrombomodulin may be useful in assessing the state of glomerular capillary endothelial cell damage.

- 1 Tan EM, Pearson CM. Rheumatic disease sera reactive with capillaries in the mouse kidney. *Arthritis Rheum* 1972;15:23-8.
- 2 Cines DB, Lyss AP, Reeber M, et al. Presence of complement-fixing antiendothelial cell antibodies in systemic lupus erythematosus. *J Clin Invest* 1984;73:611-25.
- 3 Quadros NP, Roberts-Thomson PJ, Gallus AS. IgG and IgM anti-endothelial cell antibodies in patients with collagen disorders. *Rheumatol Int* 1990;10:113-9.
- 4 Cerilli J, Holliday JE, Fesperman DP, et al. Antivascular endothelial cell antibody—its role in transplantation. *Surgery* 1977;81:132-8.
- 5 Leung DYM, Moake JL, Havens PL, et al. Lytic antiendothelial cell antibodies in hemolytic uraemic syndrome. *Lancet* 1988;ii:183-6.
- 6 Frampton G, Jayne DRW, Perry GJ, et al. Auto-antibodies to endothelial cells and neutrophil cytoplasmic antigens in systemic vasculitis. *Clin Exp Immunol* 1990;82:227-32.
- 7 Leung DYM, Colins T, Lapierre IA, et al. Immunoglobulin M antibodies present in the acute phase of Kawasaki syndrome lyse cultured vascular endothelial cells stimulated by gamma interferon. *J Clin Invest* 1986;77:1428-35.
- 8 Fujieda M, Oishi N, Kurashige T. Antibodies to endothelial cells in Kawasaki disease lyse endothelial cells without cytokine pretreatment. *Clin Exp Immunol* 1977;107:120-6.
- 9 Maruyama J, Bell C, Majerus PW. Thrombomodulin is found on endothelium of arteries, veins, capillaries, and lymphatics, and syncytiotrophoblast of human placenta. *J Cell Biol* 1985;101:363-71.
- 10 Suzuki K, Nishioka J, Hayashi T, et al. Functionally active thrombomodulin is present in human platelets. *J Biochem* 1988;104:628-32.
- 11 Ishii H, Majerus PW. Thrombomodulin is present in human plasma and urine. *J Clin Invest* 1985;76:2178-81.
- 12 Ishii H, Uchiyama H, Kazama M. Soluble thrombomodulin antigen in conditioned medium is increased by damage of endothelial cells. *Thromb Haemost* 1991;65:618-23.
- 13 Endo S, Inada K, Nakae H, et al. Blood levels of endothelin-1 and thrombomodulin in patients with disseminated intravascular coagulation and sepsis. *Res Commun Mol Pathol Pharmacol* 1995;90:277-88.
- 14 Kodama S, Uchijima E, Nagai M, et al. One-step sandwich enzyme immunoassay for soluble human thrombomodulin using monoclonal antibodies. *Clin Chim Acta* 1990;192:191-200.
- 15 Honda M, Yamamoto M, Watanabe K, et al. Role of antiphospholipid antibodies in the pathogenesis of thrombosis in antiphospholipid syndrome. *Acta Hematol Jpn* 1990;53:1620-9.
- 16 Iwashima Y, Sato T, Watanabe K, et al. Elevation of plasma thrombomodulin level in diabetic patients with early diabetic nephropathy. *Diabetes* 1990;39:983-8.
- 17 Nitta K, Simonson MS, Dunn MJ. The role and regulation of prostaglandin biosynthesis in cultured bovine glomerular endothelial cells. *J Am Soc Nephrol* 1991;2:156-63.
- 18 Rosenbaum J, Pottinger BE, Woo P, et al. Measurement and characterization of circulating anti-endothelial cell IgG in connective tissue disease. *Clin Exp Immunol* 1988;72:450-6.
- 19 Hansen MB, Nielsen SE, Berg K. Re-examination and further development of a precise and rapid dye method for measuring cell growth/cell kill. *J Immunol Methods* 1989;119:203-10.
- 20 Del Papa N, Meroni PL, Barcellini W, et al. Antibodies to endothelial cells in primary vasculitides mediate in vitro endothelial cytotoxicity in the presence of normal peripheral blood mononuclear cells. *Clin Immunol Immunopathol* 1992;63:267-74.
- 21 Matsuda M. Experimental glomerular tissue injury induced by immunization with cultured endothelial cell plasma membrane. *Acta Pathol Jpn* 1988;38:823-39.
- 22 Fujieda M, Oishi N, Kurashige T, et al. Antiendothelial cell antibodies and cytotoxicity against endothelial cells in various vasculitis of childhood. *Jpn J Pediatr Nephrol* 1995;8:145-50 (in Japanese).
- 23 Fujieda M, Oishi N, Naruse K, et al. Antiendothelial cell antibodies in Henoch-Schönlein purpura in childhood: frequency and clinicopathologic significance. *Nephron* (in press).
- 24 Nash MC, Shah V, Dillon MJ. Soluble cell adhesion molecules and von Willebrand factor in children with Kawasaki disease. *Clin Exp Immunol* 1995;101:13-17.
- 25 Voskuyl AE, Martin S, Melchers I, et al. Levels of circulating intercellular adhesion molecule-1 and 3 but not circulating endothelial leukocyte adhesion molecule are increased in patients with rheumatoid vasculitis. *Br J Rheumatol* 1995;34:311-5.
- 26 Söylemezöglü O, Sultan N, Gursel T, et al. Circulating adhesion molecules ICAM-1, E-selectin, and von Willebrand factor in Henoch-Schönlein purpura. *Arch Dis Child* 1996;75:507-11.
- 27 Yamamoto T, Miyata H, Michihata I, et al. Evaluation of plasma and urinary thrombomodulin and cytokines levels in the patients with hemolytic uremic syndrome. *Infect Immun Child* 1995;7:103-9.
- 28 Ohdama S, Takano S, Miyake S, et al. Plasma thrombomodulin as a marker of vascular injuries in collagen diseases. *Am J Clin Pathol* 1994;101:109-13.
- 29 Tanaka A, Ishii H, Hiraiishi S, et al. Increased thrombomodulin values in plasma of diabetic men with microangiopathy. *Clin Chem* 1991;37:269-72.