

## HISTOPATHOLOGICAL OBSERVATIONS OF GOLDEN HAMSTERS INFECTED WITH AN ECUADORIAN ISOLATE OF *LEISHMANIA MEXICANA*

ABDUL MANAN BHUTTO<sup>1</sup>\*, SHIGEO NONAKA<sup>2</sup>, EDUARDO A. GOMEZ L.<sup>3</sup>,  
YOSHIHISA HASHIGUCHI<sup>4</sup> AND MASATO FURUYA<sup>5</sup>

Received May 18 1992/Accepted June 30 1992

**Abstract:** An experimental study was performed to investigate the *Leishmania mexicana* infection in golden hamsters. The animals were infected with *L. mexicana* from Ecuador. At the autopsy 6 months after inoculation, the inoculated sites were shallow, ulcerative and covered with thick crusts. No cutaneous metastasis was observed on other exposed parts of the body. Histologically, specimens of both the nose and footpads showed large numbers of amastigotes with extensive infiltration of histiocytes and lymphocytes and, to some extent, of neutrophils, eosinophils and plasma cells. Large numbers of mast cells were evident in the upper and lower dermis of granulomatous lesions. Amastigotes were found in the macrophages inside the large parasitophorous vacuoles, mostly at the central part of the lesion. Amastigotes were also observed in the liver and spleen by electron microscope but the number was fewer in visceral than in cutaneous sections. Regular destruction of parasites was observed within macrophages in all the cutaneous and visceral sections indicating the phagocytizing role of these cells against parasites.

### INTRODUCTION

American cutaneous leishmaniases, caused by *Leishmania mexicana* and *L. (Leishmania) braziliensis* complex, are widely endemic in Central and South America. Among the many species of the New World *Leishmania*, *L. mexicana* (= *L. mexicana mexicana*) is well known to be responsible for a variety of disease forms that show everything from localized simple mild lesions to generalized diffuse lesions and that are distributed widely from lowlands to Andean highlands. In Ecuador, the species *L. mexicana* was isolated from both Andean highland and Pacific lowland patients (Armijos *et al.*, 1990; Hashiguchi *et al.*, 1991). However, the clinical manifestations caused by *L. mexicana* had a tendency to vary depending on several unknown factor(s), such as the geographical distribution and immunological

- 1 Department of Dermatology, Nagasaki University School of Medicine, 1-7-1 Sakamoto-machi, Nagasaki 852, Japan (\*correspondent author)
- 2 Department of Dermatology, School of Medicine, University of the Ryukyus, 207 Uehara, Nishihara, Okinawa 903-12, Japan
- 3 Departamento de Medicina Tropical, Facultad de Medicina, Universidad Catolica Santiago de Guayaquil, Guayaquil, Ecuador
- 4 Department of Parasitology, Kochi Medical School, Nankoku, Kochi 783, Japan
- 5 Institute for Laboratory Animals, Kochi Medical School, Nankoku, Kochi 783, Japan

or physiological conditions of human hosts (Hashiguchi *et al.*, 1991 our unpublished data). In order to investigate the factor(s) involved, we launched a comparative study of Ecuadorian leishmaniasis between the lowlands and highlands, carrying out histopathological and electromicroscopical observations on biopsy materials from humans and experimental animals. As a first step, an attempt was made in the current study to obtain baseline data (information) on the pathology of experimental (animal) leishmaniasis caused by *L. mexicana* isolated from the Pacific lowlands of Ecuador. Together with the ultrastructural study of the Ecuadorian forms of leishmaniasis reported previously (Bhutto *et al.*, 1992), the information reported here will provide a clearer understanding of this disease in Ecuador. The present report focuses mainly on the results of histopathological findings of the dermal lesions (ulcers) of hamsters infected experimentally and the visceral organs invaded by the parasite *L. mexicana*.

## MATERIALS AND METHODS

### **Animals:**

Male golden hamsters, 100 to 150 g and 7 weeks of age, were used. The animals were fed a standard pellet diet and given water *ad libitum*.

### **Parasites and mode of infection:**

Parasites were isolated from an Ecuadorian leishmaniasis patient and maintained *in vitro* for several months before animal inoculation. They were identified as *L. mexicana* (MHOM/EC/INH690) using isoenzyme electrophoresis by Dr. T. Agatsuma, Department of Parasitology, Kochi Medical School, Japan. The promastigotes of log phase were inoculated to the nose and hind footpads of 10 hamsters. Each hamster received  $1 \times 10^7$  promastigotes. The development of lesions was observed and recorded periodically during infection.

### **Histopathology:**

At about 6 months after post-infection the animals were sacrificed and specimens were taken from central and peripheral parts of the lesions. Specimens were also taken from the liver and spleen and divided into two parts. One part was fixed in 10% formalin, from which paraffin sections were made and 5  $\mu$ m sections were stained with hematoxylin-eosin. For the differentiation of mast cells, sections were also stained with toluidine blue (pH 5.0).

### **Electron Microscopy:**

The other part of autopsy materials was cut into 2-3 mm pieces and fixed with 2% paraformaldehyde and 2% glutaraldehyde in 0.1 M cacodylate buffer (pH 7.4). The tissues were then washed with 0.1 M cacodylate buffer and post-fixed in 2% osmium oxide for 2 hr. After dehydration in different concentrations of alcohol, specimens were embedded in epon 812. One micron semi-thin sections were cut with a glass knife on an LKB ultratome and stained with toluidine blue. Ultra-thin sections were cut with a diamond knife, stained with lead citrate and uranyl acetate, and examined under a JEM 1200 EX electron microscope (JEOL, Japan).

## RESULTS

Almost all the hamsters inoculated with *L. mexicana* promastigotes developed erythematous lesions at the site of inoculation. The lesions gradually changed into nodules,

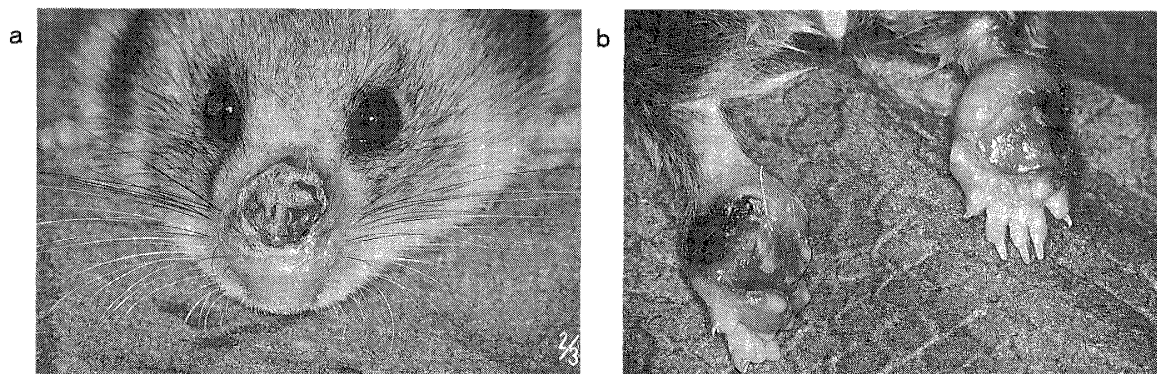


Figure 1 The inoculated sites of the golden hamsters infected with *L. mexicana* isolated from Ecuadorian patient. Shallow ulcers are visible on the (a) nose and (b) both hind footpads.

ultimately resulting in ulcers. At the time of autopsy, the inoculated sites of the nose and both hind footpads were observed as swollen and large ulcerations (Figs. 1a, b). The ulcers were covered with thick crusts. There was no metastasis or nodule formation on other areas of the body surface.

**Light microscopic findings:**

No significant epidermal changes were seen in either the nasal or the footpad sections. The epidermis was intact and thin at the center of the lesion, and crusts and parakeratosis were present in some parts of the specimens. In the dermis, histiocytes were predominant in the sections, and most of these contained numerous amastigotes in the large vacuoles, particularly at the central part of the lesions (Figs. 2a, b). Huge numbers of lymphocytes accumulated around the parasitized macrophages in the peripheral part of the lesions (Figs. 3a, b). Neutrophils, eosinophils and plasma cells were also seen throughout the specimens. Many mast cells were observed in the upper dermis in both the nasal and footpad sections (Figs. 4a, b). Mast cells were located in the areas of the dermis free from parasites but absent

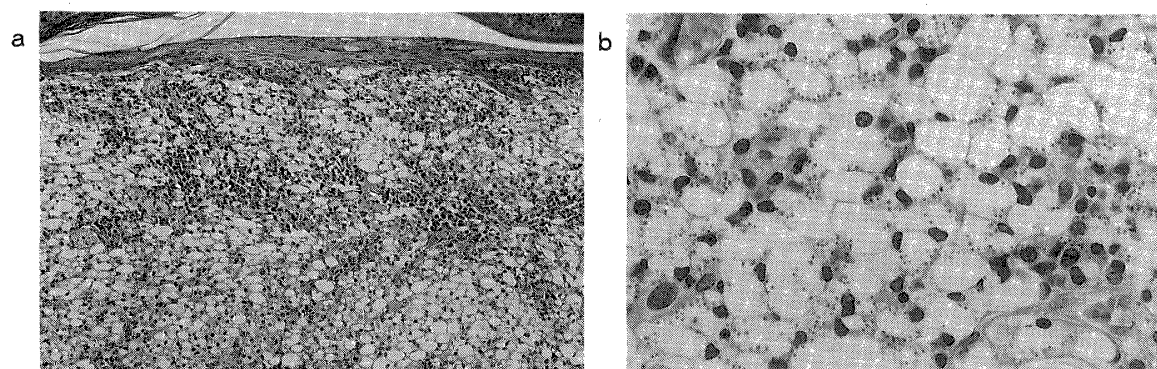


Figure 2 a, Light photomicrograph of formalin embedded section from the nose of a golden hamster infected with *L. mexicana*, showing the extensive infiltration of histiocytes and the formation of parasitophorous vacuoles. b, Many parasites invaded by macrophages are visible inside the parasitophorous vacuoles. (H & E stain  $\times 40$ ,  $\times 160$ )

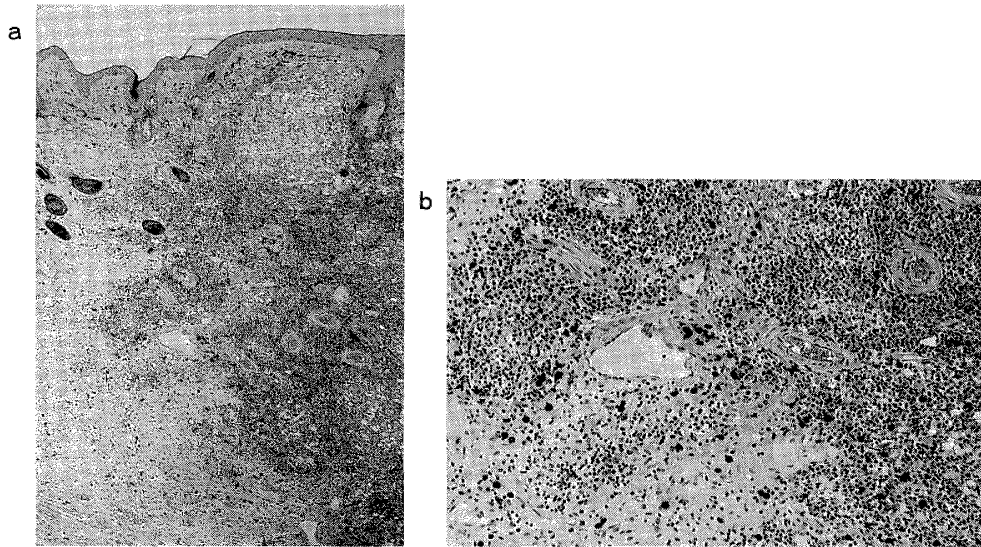


Figure 3 a, Footpad section, showing the presence of large number of lymphocytes and the parasitized macrophages. b, high magnification of 3a, showing the perivascular infiltration of lymphocytes. (H & E stain  $\times 16$ ,  $\times 40$ )

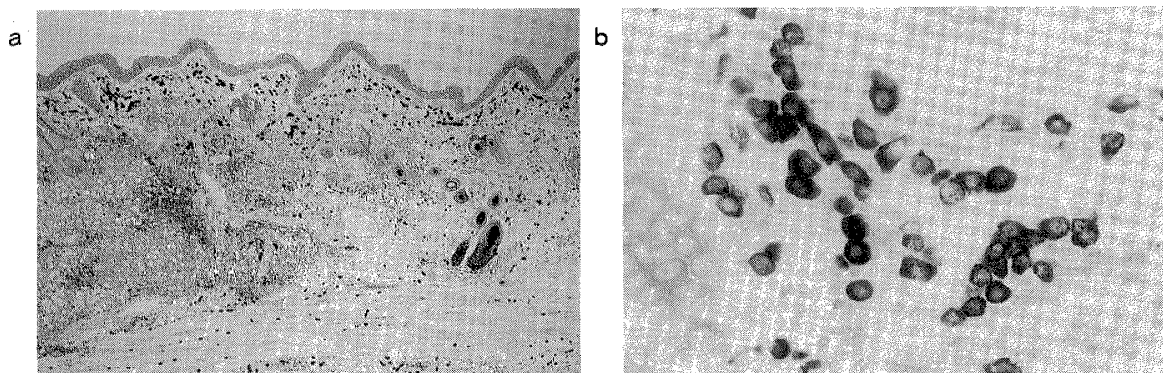


Figure 4 a, Huge number of mast cells in the upper and lower dermis. b, High magnification of 4a. (Toluidine blue stain  $\times 16$ ,  $\times 160$ )

in the areas where macrophages were occupied with parasites. Focal necrosis was also recognized in the deep dermis.

In the liver and spleen sections, it was difficult to find the parasites because of the very small number.

#### **Electron microscopic findings:**

The epidermis of inoculated sites was free from the invasion of parasites. In the dermis, parasites were found both intracellularly and extracellularly. Amastigotes in the cytoplasm of macrophages were located either inside or outside vacuoles (Figs. 5 and 6). More than one vacuole was seen in most of the macrophages and large numbers of amastigotes were present in most of the vacuoles. Some parasite-free vacuoles were also seen, and these connected

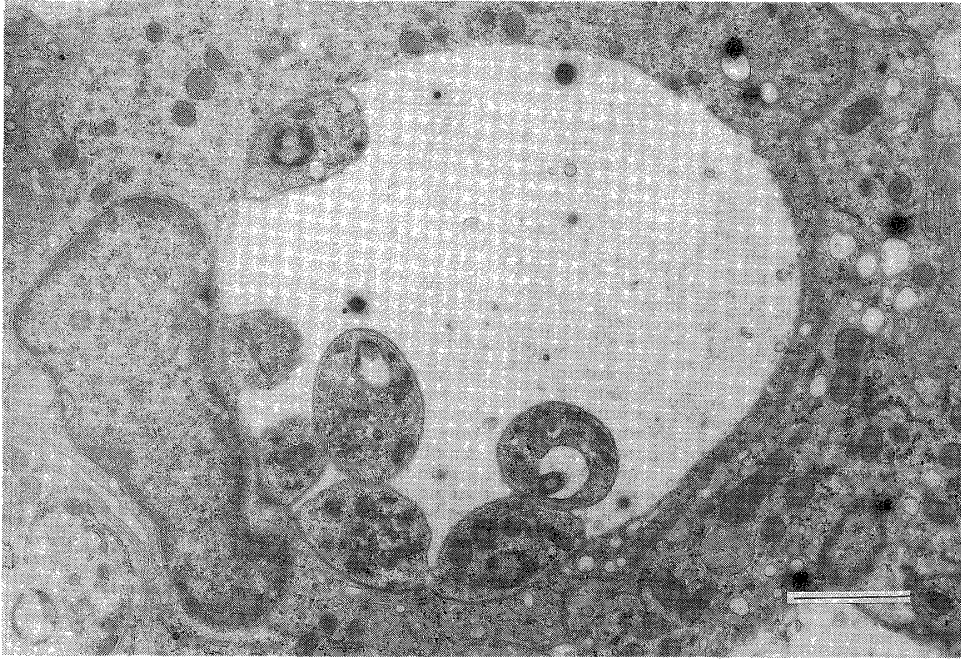


Figure 5 Electron micrograph. A group of *L. mexicana* parasites are evident inside the parasitophorous vacuole of macrophage. bar=2  $\mu\text{m}$

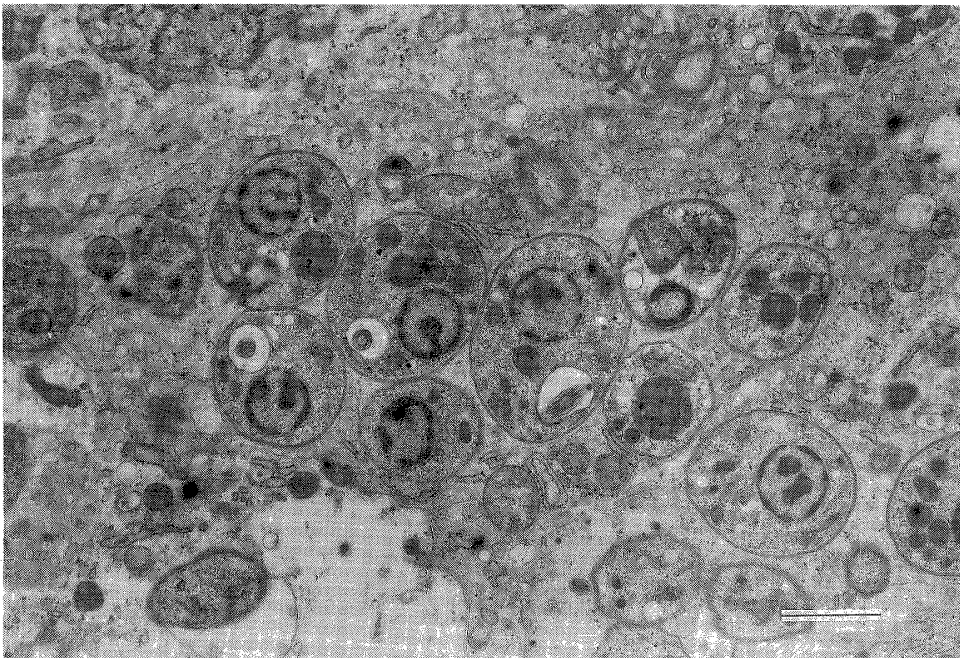


Figure 6 Figure showing the parasites inside the cytoplasm of macrophage without formation of vacuole. Mitochondria of the macrophage are also visible. bar=2  $\mu\text{m}$



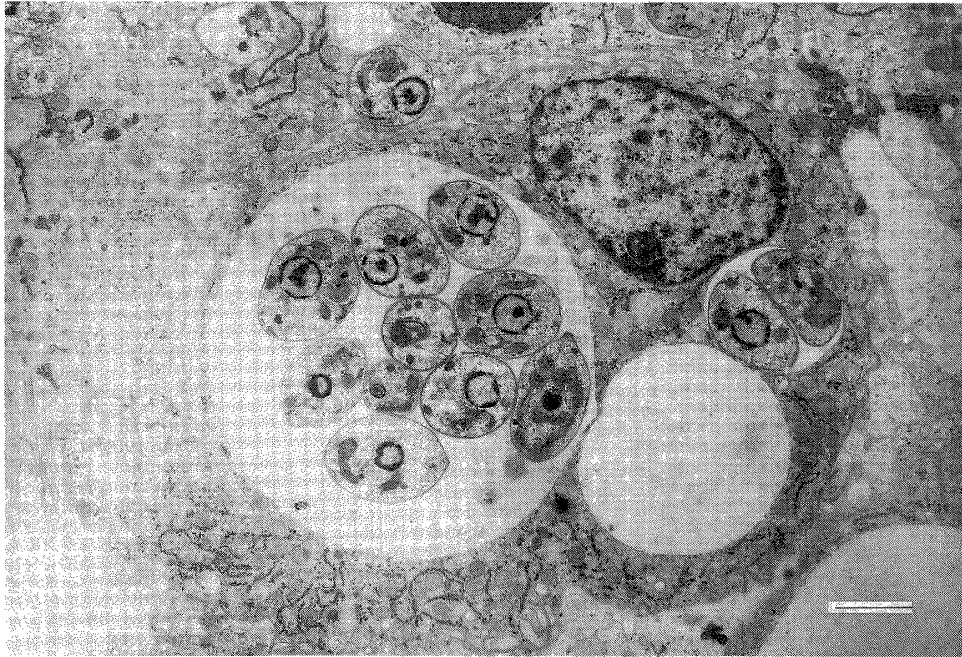


Figure 7 Various numbers of parasites with and without vacuoles. A small vacuole free of parasites is also visible near the large parasitophorous vacuole. bar=2  $\mu\text{m}$

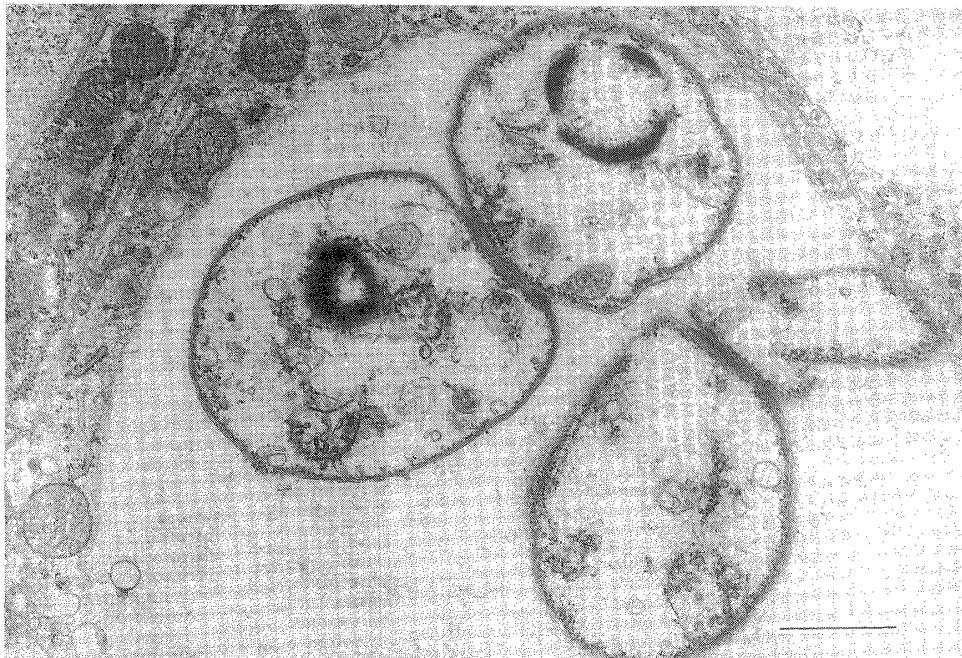


Figure 8 The degeneration of some *L. mexicana* parasites inside the macrophage of the liver. bar=1  $\mu\text{m}$

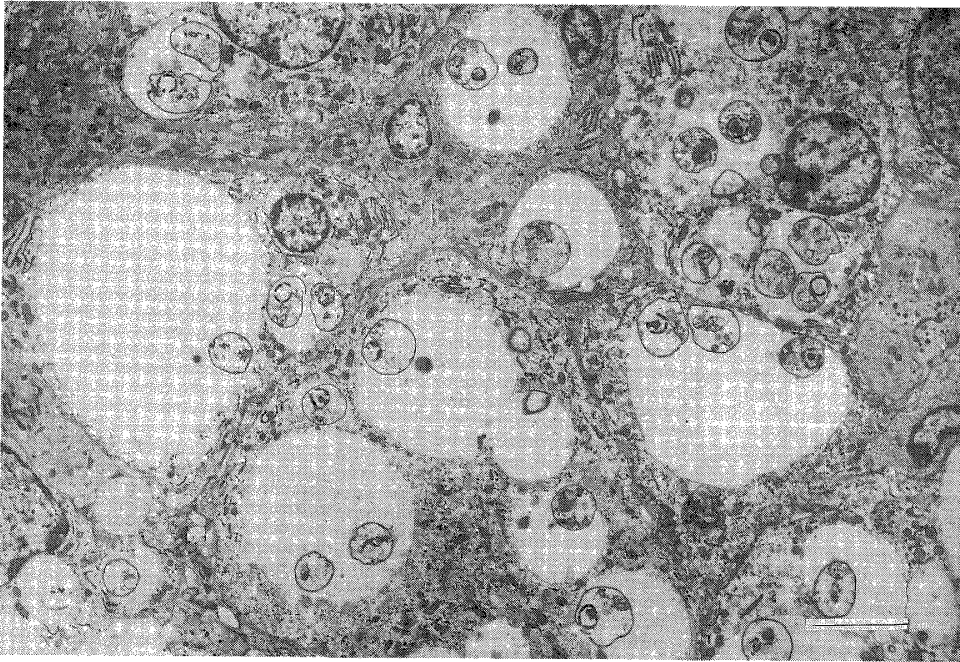


Figure 9 Electron micrograph of the section from the nose. Parasites are in various stages of degeneration. bar=5  $\mu$ m

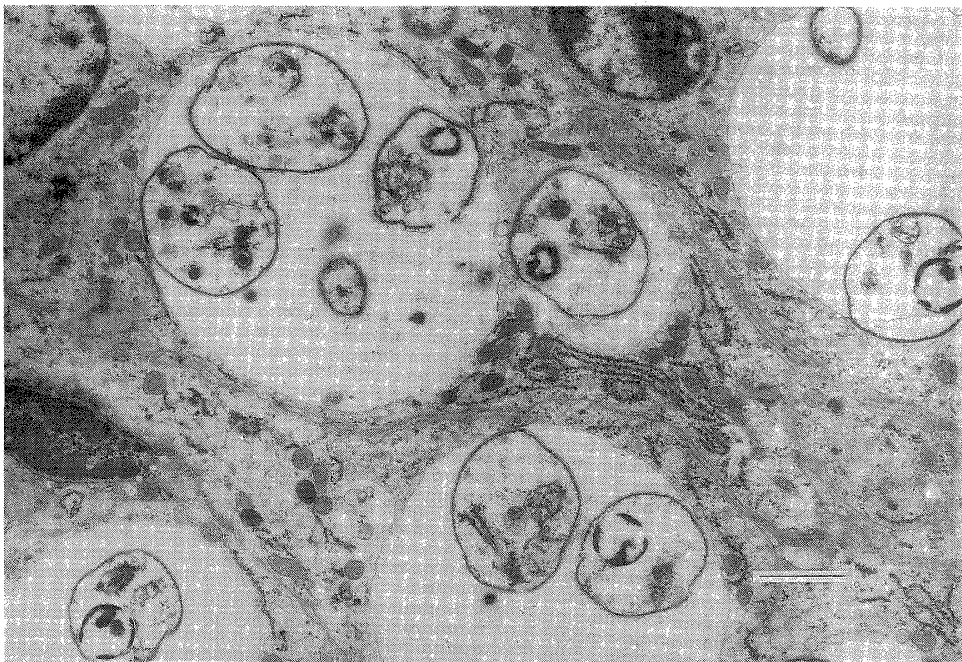


Figure 10 Degenerating parasites inside the parasitophorous vacuole of macrophage in the right footpad. bar=2  $\mu$ m

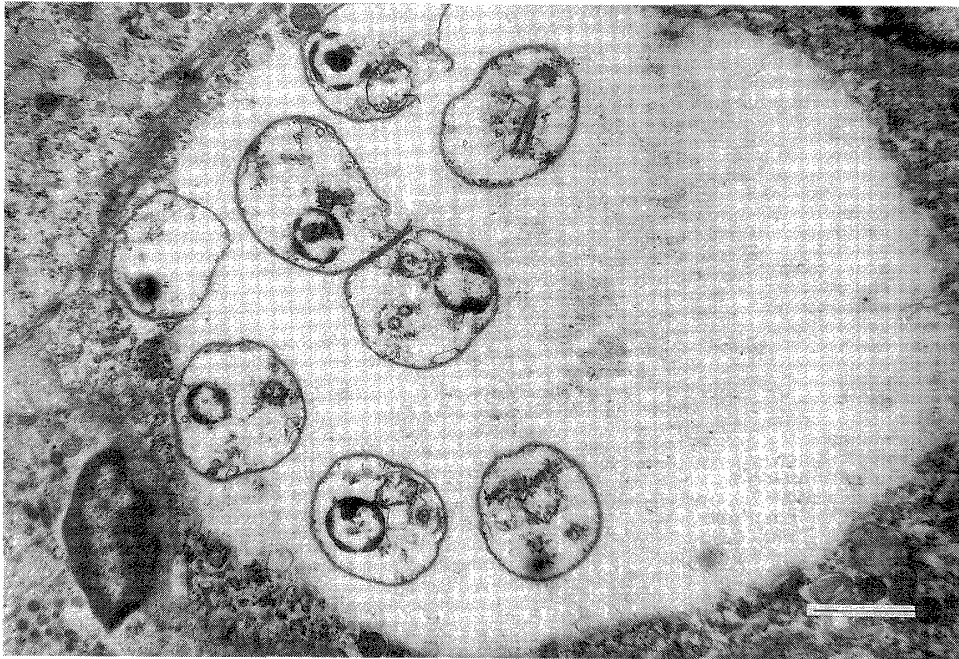


Figure 11 Section from left footpad. All the parasites are in various phases of degeneration inside the vacuole of macrophage. bar=2  $\mu$ m

with parasitophorous vacuoles (Fig. 7). Parasites were neither inside the mast cells nor in the eosinophils or neutrophils.

Parasites were also found in the liver and spleen of hamsters infected experimentally with *L. mexicana* from Ecuador. They were located within the macrophages but very few in number. Regular degeneration of parasites was noted within macrophages inside or outside the vacuoles in all the cutaneous and visceral sections (Figs. 8, 9, 10 and 11). Morphologically, the normal amastigotes were rounded or elongated, surrounded by two layers of membranes and containing a rounded nucleus with a small nucleolus. The flagellum, flagellar pocket, kinetoplast, mitochondria, golgi apparatus, lysosomes, vacuoles and electron-dense granules in vacuoles were distinguishable (Figs. 12a, b).



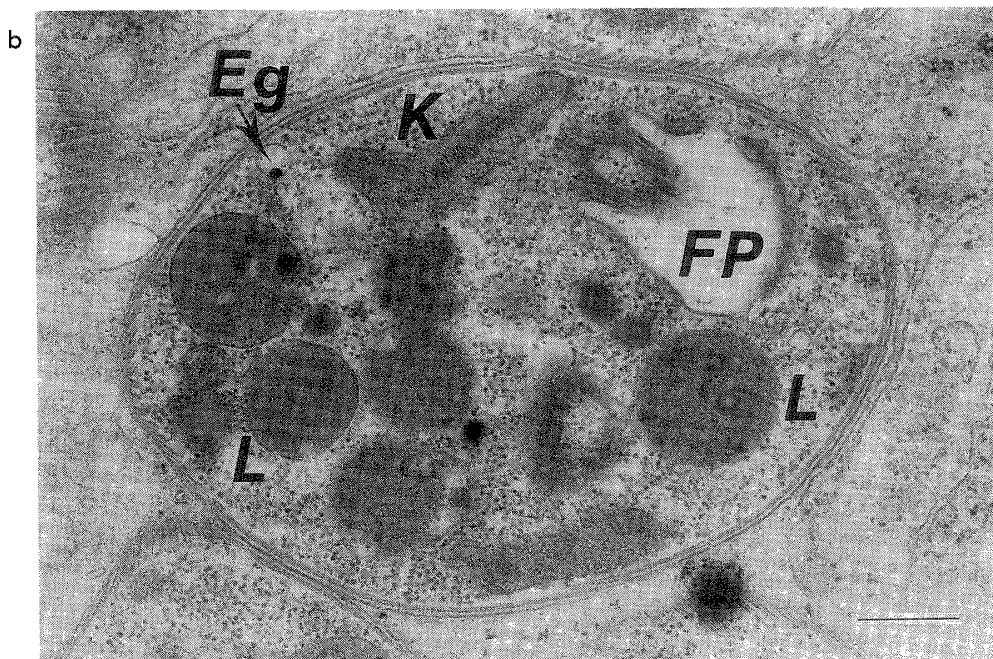
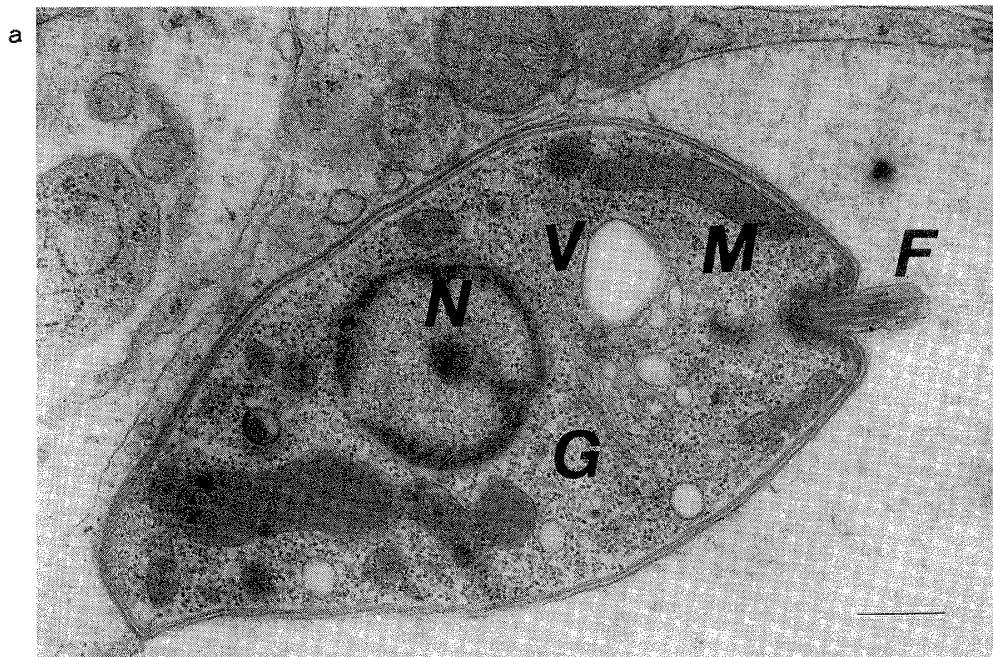


Figure 12a, b Ultrastructure of the *L. mexicana* parasite. F=flagellum, FP=flagellar pocket, K=kinetoplast, M=mitochondria, N=nucleus with small nucleolus, G=golgi apparatus, L=lysosomes, V=vacuoles and Eg=electron-dense granules inside the vacuole. bar=500 nm

## DISCUSSION

After the autopsy of hamsters 6 months after inoculation with *L. mexicana*, we observed shallow ulcers covered by thick crusts over the nose and both hind footpads in all the animals, confirming the finding that the hamster is a good animal model for *L. mexicana* infection (Wilson *et al.*, 1979; Bretana *et al.*, 1983).

An understanding of the relationship between *L. mexicana* and the cells of the host Ecuadorian patient is essential to the elucidation of the pathogenesis of the disease in that country. Observations of our specimens revealed that once the parasite is phagocytized by macrophage it is enclosed by phagolysosome. Then, the phagolysosome starts to distend and inside it multiplication of parasites takes place (Berman *et al.*, 1979).

With regard to the development of experimental cutaneous lesions, Bretana *et al.* (1983) proposed 1) that toxic factors from the amastigote inhibit the action of lysosomal enzymes; 2) that this causes the phagolysosome to become enlarged and new vacuoles to be invaded with parasites; 3) that extensive enlargement of the vacuoles and certain other factors cause the rupture of cell membranes; and 4) that repetition of this process results in ulceration at the sites. From the observations of many stained specimens in this study, we concluded that a similar process of ulceration takes place in hamsters infected with *L. mexicana* from Ecuador.

In the present light microscopic sections, large numbers of *L. mexicana* amastigotes inside the parasitophorous vacuoles were observed in the nose and footpad sections but it was difficult to find the amastigotes in the liver and spleen sections. The amastigotes in the liver and spleen were confirmed in ultra-thin sections but the number was limited, indicating the active multiplication of *L. mexicana* (dermatophilic) parasites in the inoculated sites (nose and footpads) but not in the liver and spleen. These findings suggest that although *L. mexicana* inoculated to the nose and footpads of hamsters can disseminate from the cutaneous sites to the liver and spleen, they do not replicate in these organs.

Similar results have also been presented by Hill (1988), who showed the possibility of dissemination of *L. amazonensis* to the liver and spleen in two different strains of mice. However, the metastasis (visceral dissemination) was not observed in C3H mice infected with *L. mexicana* (Grimaldi *et al.*, 1980). When the five different strains of mice were infected with *L. mexicana*, different responses were observed including the appearance of metastatic lesions in the tail of BALB/C mice (Perez *et al.*, 1979). Recently, *L. amazonensis*, well known as a causative agent of human cutaneous leishmaniasis, was isolated from the bone marrow of a Brazilian patient with visceral leishmaniasis (Barral *et al.*, 1986). With regard to *L. mexicana* infection, therefore, visceral dissemination may be observed in humans in future examinations as it was in the present animal (hamster) model.

There is controversy about the role of the macrophage in killing parasites intracellularly. Previously, we found the degeneration of parasites inside the macrophages in human specimens (Bhutto *et al.*, 1992). In the present study, large numbers of parasites also showed degeneration within macrophages inside and outside the vacuoles in all of the cutaneous and visceral specimens. This indicates the active role of macrophages in the destruction of parasites intracellularly, although the destruction mechanism is unknown. Intracellular degeneration of parasites inside macrophages has been reported in other human cases (Sandbank, 1976) and experimental works (Mauel *et al.*, 1978). On the other hand, however,

Bretana *et al.* (1983) showed that macrophages are incapable of destroying the parasites intracellularly.

Immunocytochemical and electron microscopic studies in animals have suggested that T-cells provide lymphokines (cytokines) that can activate the host macrophage to destroy the parasites intracellularly, or that T-cells play a cytotoxic role, killing the infected macrophages and helping to destroy the liberated extracellular parasites (McElrath *et al.*, 1987). Sypek *et al.* (1984) believed that intracellular destruction of *L. tropica* can take place only by the direct cell contact mechanism between lymphocytes and macrophages. Moreover, Murray *et al.* (1982) demonstrated the killing of *L. donovani* amastigotes inside macrophages by the oxygen dependent mechanism and concluded that non-activated phagocytes may display effective microbicidal activity against intracellular parasites utilizing the oxygen dependent mechanism.

From the present hamster and *L. mexicana* model, we propose that some unknown factor/factors (as discussed above) under host immune mechanism(s) play an important role and promote the destruction of parasites inside the macrophages, and therefore that effective killing of the parasites finally might result in healing of the lesions. However, the precise conditions and mechanisms of the destruction of parasites were not elucidated in the present study. In our specimens, severe degeneration of amastigotes in large numbers of macrophages may represent a forward step in the healing process and may allow us to suggest a possible mechanism in the self-healing of the disease. We did not, however, observe the complete healing of the lesions. Our experimental study using hamsters infected with *L. mexicana* isolated from an Ecuadorian patient is a model of classic self-healing of the cutaneous form that adds to our understanding of the mechanism of the pathogenesis of Ecuadorian leishmaniasis. On the basis of the results obtained, we conclude that macrophage can destroy the parasites intracellularly under certain mechanism(s) and play an effective and major role in the spontaneous healing of the disease.

#### ACKNOWLEDGEMENTS

We thank Professor Hikotaro Yoshida, Director of the Department of Dermatology, Nagasaki University, for helpful discussions.

#### REFERENCES

- 1) Armijos, R.X., Chico, M.E., Cruz, M.E., Guderian, R.H., Kreutzer, R.D., Berman, J.D., Rogers, M.D. and Grogl, M. (1990): Human cutaneous leishmaniasis in Ecuador: Identification of parasites by enzyme electrophoresis, *Am. J. Trop. Med. Hyg.*, 42, 424-428
- 2) Barral, A., Petersen, E.A., Sacks, D.L. and Neva, F.A. (1983): Late metastatic leishmaniasis in the mouse. A model for mucocutaneous disease, *Am. J. Trop. Med. Hyg.*, 32, 277-285
- 3) Berman, J.D., Dwyer, D.M. and Wyler, D.J. (1979): Multiplication of *Leishmania* in human macrophages *in vitro*, *Infect. Immun.*, 26, 375-379
- 4) Bhutto, A.M., Okada, S., Nonaka, S., Gomez L, E.A. and Hashiguchi, Y. (1992): Ultrastructural studies on cutaneous leishmaniasis in Ecuador, *Jpn. J. Trop. Med. Hyg.*, 20, 11-21
- 5) Bretana, A., Avila J.L., Lizardo, G., Convit, J. and Rondon, A.J. (1983): *Leishmania* species: Comparative ultrastructure of experimental nodules and diffuse human cutaneous lesions in American leishmaniasis, *Exp. Parasitol.*, 55, 377-385

- 6) Grimaldi, G. Jr., Moriearty, P.L. and Hoff, R. (1980): *Leishmania mexicana*: Immunology and histopathology in C3H mice, *Exp. Parasitol.*, 50, 45-56
- 7) Hashiguchi, Y., Gomez L, E.A., Coronel, V.V., Mimori, T., Quizhpe, A.M., Grimaldi, G. Jr., Kreutzer, R.D. and Tesh, R.B. (1991): Andean leishmaniasis in Ecuador caused by infection with *Leishmania mexicana* and *L. major*-like parasites, *Am. J. Trop. Med. Hyg.*, 44, 205-217
- 8) Hill, J.O. (1988): Pathophysiology of experimental leishmaniasis: The role of parasite physiology in the development of metastatic disease, *Am. J. Trop. Med. Hyg.*, 39, 256-260
- 9) Mael, J., Buchmuller, Y. and Behin, R. (1978): Studies on the mechanisms of macrophage activation. I. Destruction of intracellular *Leishmania enriettii* in macrophages activated by cocultivation with stimulated lymphocytes, *J. Exp. Med.*, 148, 393-407
- 10) McElrath, M.J., Kaplan, G., Nusrat, A. and Cohn, Z.A. (1987): Cutaneous leishmaniasis. The defect in T cell influx in BALB/c mice, *J. Exp. Med.*, 165, 546-559
- 11) Murray, H.W. (1982): Cell-mediated immune response in experimental visceral leishmaniasis. II. Oxygen-dependent killing of intracellular *Leishmania donovani* amastigotes, *J. Immunol.*, 129, 351-357
- 12) Perez, H., Labrador, F. and Torrealba, J.W. (1979): Variations in the response of five strains of mice to *Leishmania mexicana*, *Int. J. Parasitol.*, 9, 27-32
- 13) Sandbank, M. (1976): Cutaneous leishmaniasis. Ultrastructural study of 3 cases, *Arch. Derm. Res.*, 257, 195-201
- 14) Sypek, J.P., Panosian, C.B. and Wyler, D.J. (1984): Cell contact-mediated macrophage activation for antileishmanial defence. II. Identification of effector cell phenotype and genetic restriction, *J. Immunol.*, 133, 3351-3357
- 15) Wilson, H.R., Dieckmann, B.S. and Childs, G.E. (1979): *Leishmania braziliensis* and *Leishmania mexicana*: Experimental cutaneous infections in golden hamsters, *Exp. Parasitol.*, 47, 270-283



実験的リーシュマニア症  
—エクアドルで分離された *Leishmania mexicana* 感染  
ゴールデンハムスターの組織学的検討—

A.M. BHUTTO<sup>1</sup>・野中 薫雄<sup>2</sup>・E.A. Gomez, L.<sup>3</sup>・橋口 義久<sup>4</sup>・古谷 正人<sup>5</sup>

実験はゴールデンハムスターに、*Leishmania mexicana* を感染させて行った。接種後6カ月目に屠殺した時、接種部位は厚い痂皮を付す浅い潰瘍となっていた。躯幹の他の部位には、病変を認めなかった。接種部位(鼻、足趾)標本の病理組織学的所見は、多数の amastigotes (AG)、組織球、リンパ球の広範な浸潤が見られ、好中球、好酸球、プラズマ細胞を軽度混在していた。真皮の肉芽腫性病変の上下では、マスト細胞の出現が著明であった。AGは病巣中央部のマクロファージにある、大きな空胞内に存在していた。また電顕的には、肝臓、脾臓にもAGが認められたが、皮膚に比べると数は少なかった。皮膚、および内臓のマクロファージ内で観察された寄生虫の破壊は、この細胞の貪食作用によるものと思われた。

- 
- 1 長崎大学医学部皮膚科学教室 (別冊請求先：〒852 長崎市坂本1-7-1)
  - 2 琉球大学医学部皮膚科学教室
  - 3 Departamento de Medicina Tropical, Facultad de Medicina, Universidad Catolica, Santiago de Guayaquil, Ecuador
  - 4 高知医科大学寄生虫学教室
  - 5 高知医科大学動物実験施設