

ULTRASTRUCTURAL STUDIES ON CUTANEOUS LEISHMANIASIS IN ECUADOR

ABDUL MANAN BHUTTO¹, SHIGERU OKADA¹, SHIGEO NONAKA¹,
EDUARDO A. GOMEZ L.² AND YOSHIHISA HASHIGUCHI³

Received December 4 1991/Accepted January 21 1992

Abstract: Ultrastructural observations were made of the lesions of three Ecuadorian patients with cutaneous leishmaniasis. Parasites were located both within the macrophages, either inside the intracytoplasmic vacuoles (parasitophorous vacuoles) or free in cytoplasm and outside host cells. Amastigotes were rounded or oval with a mean length of $2.62 \mu\text{m}$ (± 0.17 S.D.) and mean width of $2.18 \mu\text{m}$ (± 0.28 S.D.). Parasites showed degeneration intracellularly both within the vacuoles and in the cytoplasm of macrophages. Lymphocytes were seen in close contact with parasitized macrophages as well as directly attached to the parasites. Furthermore, spongiotic vesicle was observed in the epidermis where *Leishmania* parasites were found, surrounded by lymphocytes and other mononuclear cells. Amastigotes attached to mononuclear cells were also observed inside and between the keratinocytes. Mononuclear cells containing melanin granules showed amastigotes in their cytoplasm.

The parasite-macrophage relationship, the role of T-cells in combating the parasites and the fate of the parasites inside the host body are discussed.

INTRODUCTION

Cutaneous leishmaniasis is a tropical disease distributed widely in both the Old and New World. It is a serious dermatological problem, especially in the two continents of Africa and South America. The disease can be classified largely into two forms: an Old World form caused mainly by *Leishmania tropica* complex and a New World form caused by *Leishmania* (*Viannia*) *braziliensis* and *L. (Leishmania) mexicana* complexes (Lainson and Shaw, 1987; Pearson and Sousa 1985). In order to obtain information on the clinical, epidemiological and immunological features of the latter form of the disease in Ecuador we performed detailed investigations at different endemic sites. The results have already been reported by Nonaka *et al.* (1990a, b) and Hashiguchi *et al.* (1990, 1991).

Cutaneous leishmaniasis is prevalent throughout Ecuador and six *Leishmania* species (*L. braziliensis*, *L. panamensis*, *L. guyanensis*, *L. amazonensis*, *L. mexicana* and sp. near *L. major*) have been recorded from the country to date based on zymodeme, serodeme and schizodeme analysis of samples from humans and animals (Mimori *et al.*, 1989; Hashiguchi *et al.*, 1990,

1 Department of Dermatology, Nagasaki University, School of Medicine, Nagasaki 852, Japan.

2 Departamento de Medicina Tropical, Facultad de Medicina, Universidad Catolica Santiago de Guayaquil, Guayaquil, Ecuador.

3 Department of Parasitology, Kochi Medical School, Nankoku, Kochi 783, Japan.

1991; Armijos *et al.*, 1990). Morphology and ultrastructure are also useful in differentiation of *Leishmania* species, although less information is available on these methods.

This article reports the results of an ultrastructural study of the cutaneous lesions of Ecuadorian leishmaniasis patients, and is intended to give a better understanding of the morphology and nature of *Leishmania* parasites in the country.

MATERIALS AND METHODS

Patients:

The Ecuadorian patients with cutaneous leishmaniasis, being of different ages and sex, were diagnosed on the basis of clinical features and history. The clinical and histopathological features of the three patients, i.e., I-02 (*L. guyanensis* infection), I-04 (*L. panamensis* infection) and I-25 (*Leishmania* sp., as yet characterized) were described in a previous articles (Nonaka *et al.*, 1990a, b). None of these patients had received treatment before biopsies were taken.

Processing of biopsy material:

Four-millimeter punch biopsies were taken under local anaesthesia from the edge of ulcers or nodules and fixed in different fixatives. The biopsy material was divided into two parts, one of which was fixed in 10% formalin and then embedded in paraffin. Five-micron sections were cut and stained with haematoxylin-eosin. The other part was cut into small pieces and fixed in cold 2% paraformaldehyde and 2% glutaraldehyde in 0.1 M cacodylate buffer (pH 7.4). The tissues were then washed with 0.1 M cacodylate buffer, and post fixed in 2% osmium tetroxide for 2 hrs. After dehydration in different concentrations of alcohol, the specimens were embedded in Epon 812. One micron semi-thin sections were cut with a glass knife on an LKB ultratome and stained with toluidine blue. Ultra-thin sections were cut with a diamond knife, stained with lead citrate and uranyl acetate, and examined under a JEM 1200 EX electron microscope (JEOL Japan).

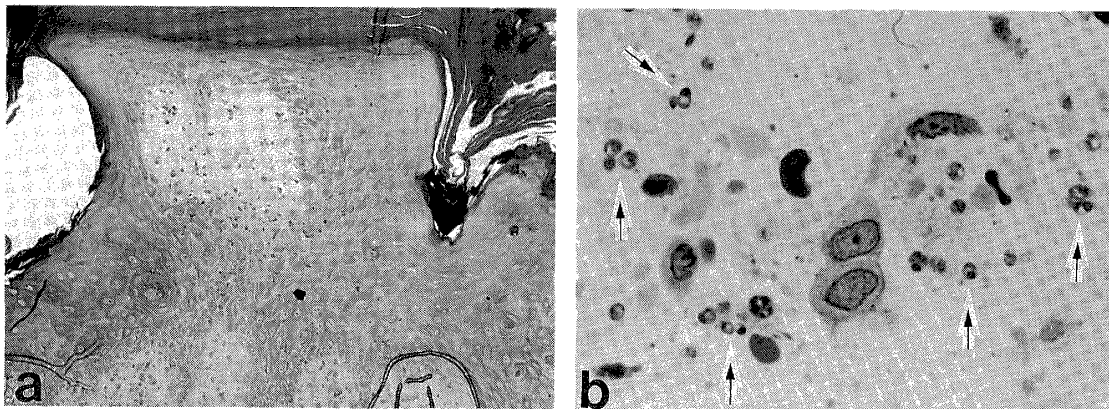


Figure 1 Light micrograph of an epon embedded semi-thin section of cutaneous leishmaniasis. a) spongiotic vesicle in the epidermis
b) arrows indicate the amastigotes inside the epidermal vesicle.
(Toluidine blue stain $\times 100$, $\times 400$)

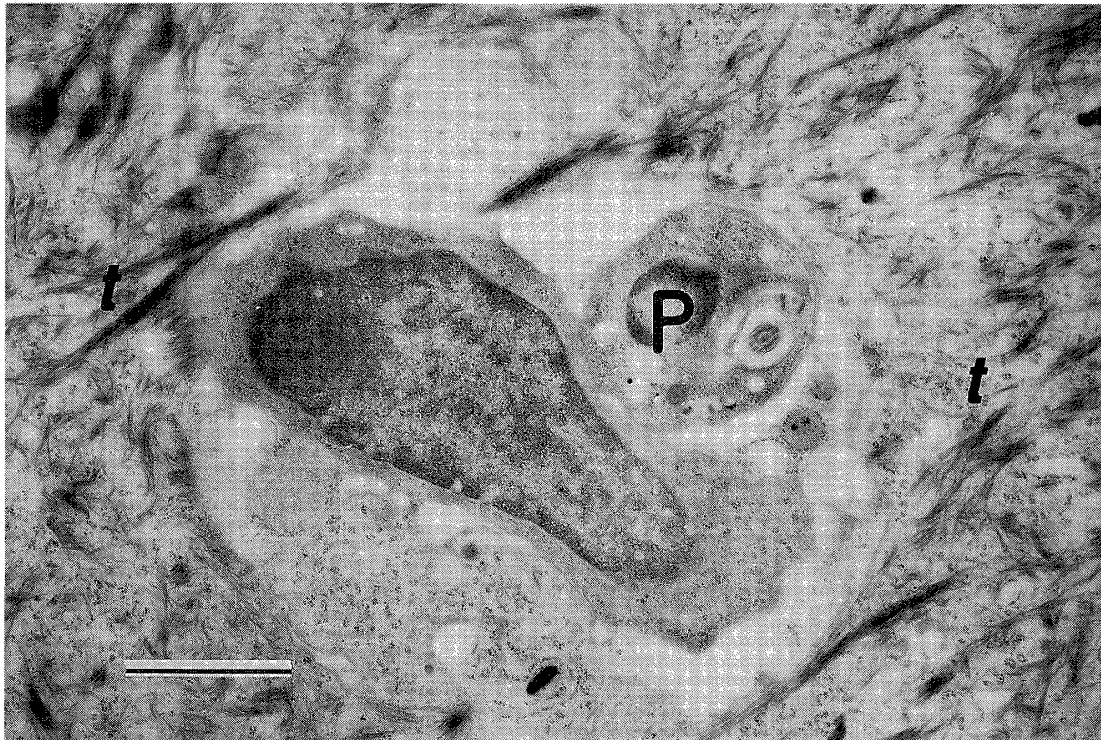


Figure 2 Electron micrograph of cutaneous leishmaniasis in Ecuador. *Leishmania* parasite (P) is in close contact with the mononuclear cell surrounded by tonofibrils (t) in the epidermis. bar=2 μ m.

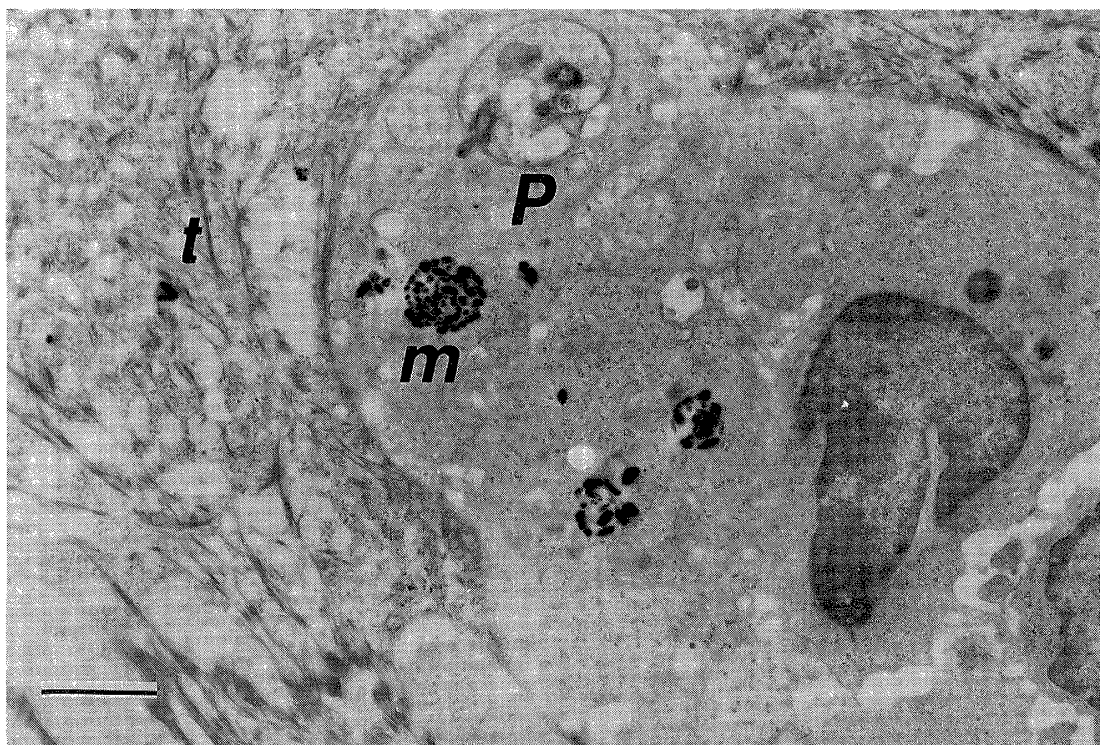


Figure 3 In the epidermis, a mononuclear cell with melanin granules (m) containing one *Leishmania* parasite (P) in its cytoplasm. (t) indicates the tonofibrils. bar=2 μ m.

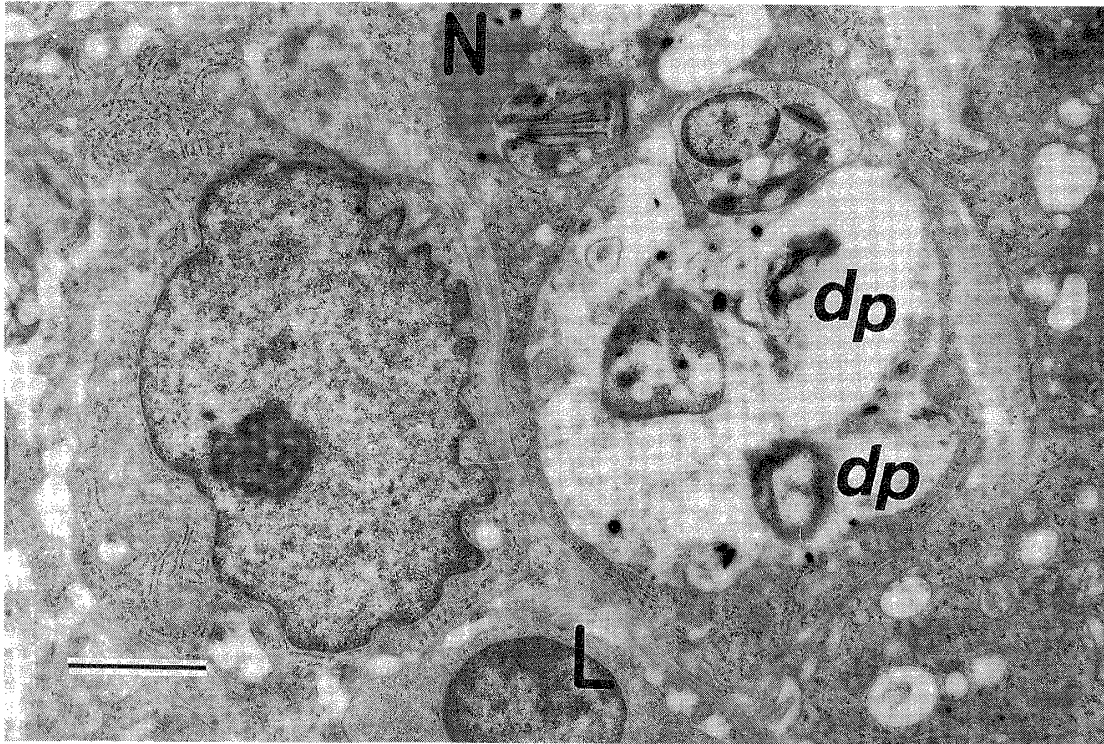


Figure 4 In the dermis, degeneration of some *Leishmania* parasites (dp) is visible inside the parasitophorous vacuole of macrophage. The host cell appears to be under parasitic attack and shows damage to the host cell nucleus (N). A lymphocyte (L) is also visible near the vacuole. bar=2 μ m.

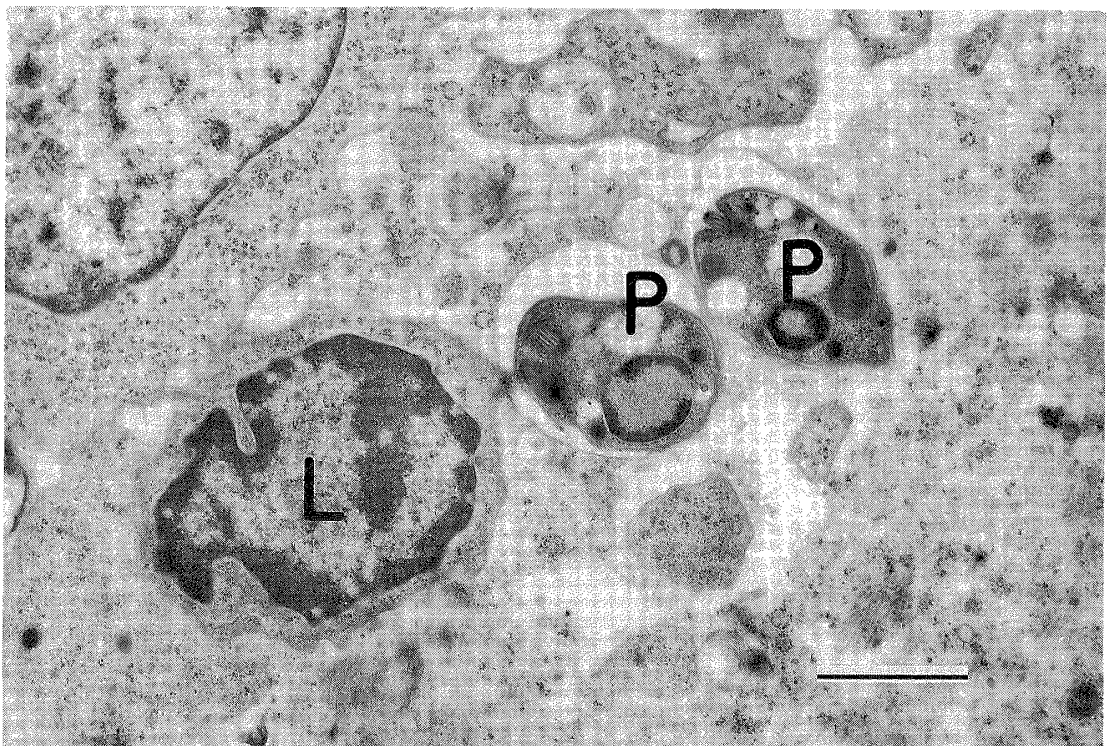


Figure 5 A lymphocyte (L) showing direct attachment to the parasites (P) in the dermis. bar=2 μ m.

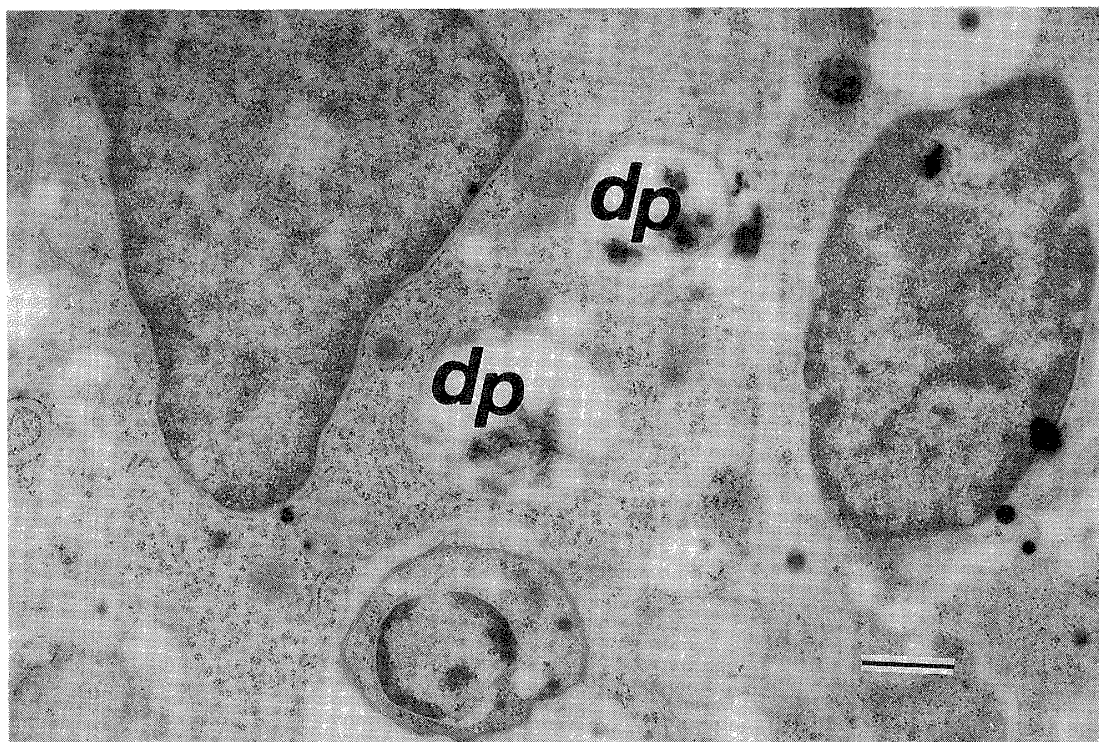


Figure 6 Degeneration of parasites (dp) inside the cytoplasm of host macrophage, with one parasite still intact. bar=1 μ m.

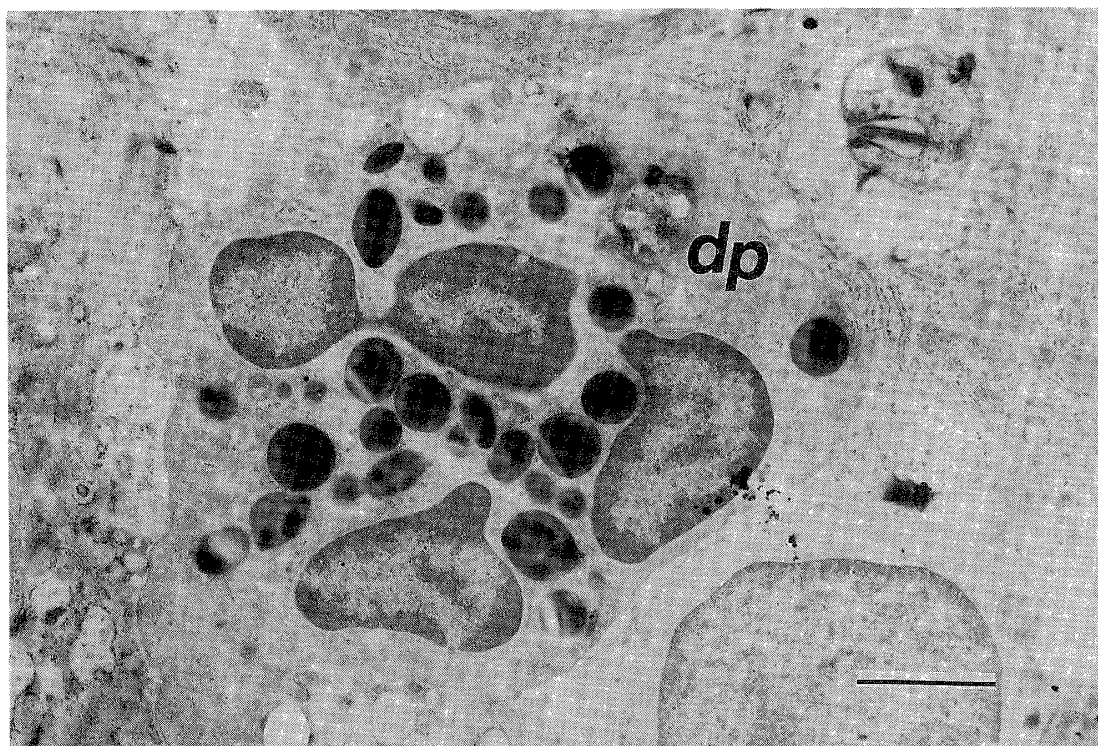


Figure 7 *Leishmania* parasite undergoing a degeneration process (dp) in the cytoplasm of eosinophil. One parasite seems to be outside the cell. bar=2 μ m.

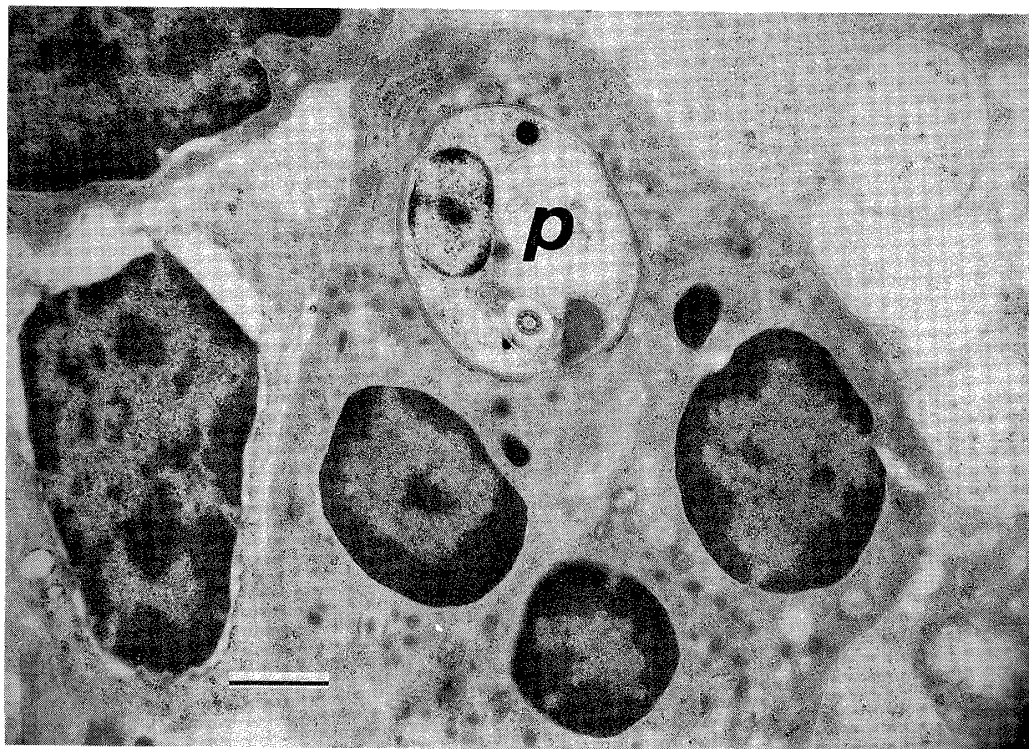


Figure 8 *Leishmania* parasite (P) is present in the cytoplasm of neutrophil.
bar=1 μ m.

RESULTS

Light microscopic observations:

Along with other minor alterations, an intraepidermal spongiotic vesicle was observed in the epidermis of one (I-25) of the three patients (Fig. 1). *Leishmania* parasites and mononuclear cells were observed inside the epidermal vesicle and between the keratinocytes. The dermis showed cellular infiltration with a great number of amastigotes.

Electron microscopic observations:

1. Epidermis:

Leishmania parasites inside the epidermal vesicle were found in ultra-thin sections, where lymphocytes and other mononuclear cells were present near the parasites. Parasites were also observed in and between the keratinocytes, either attached to mononuclear cells that may have been macrophages (Fig. 2) or free in the microvesicle abscesses. A mononuclear cell containing melanin granules had a *Leishmania* parasite in its cytoplasm (Fig. 3).

2. Dermis:

Parasites were found both intracellularly and extracellularly. Amastigotes located in the cytoplasm of macrophages either inside or outside the parasitophorous vacuoles. Parasites in the macrophages were varied from 1 to 14 in number either inside the vacuole or free in the cytoplasm, showed the multiplication of parasites inside the cells. Usually, one parasitized vacuole was seen in one macrophage. Many host macrophages were seen activated against the phagocytized parasites. Electron-dense granules were frequently observed in the

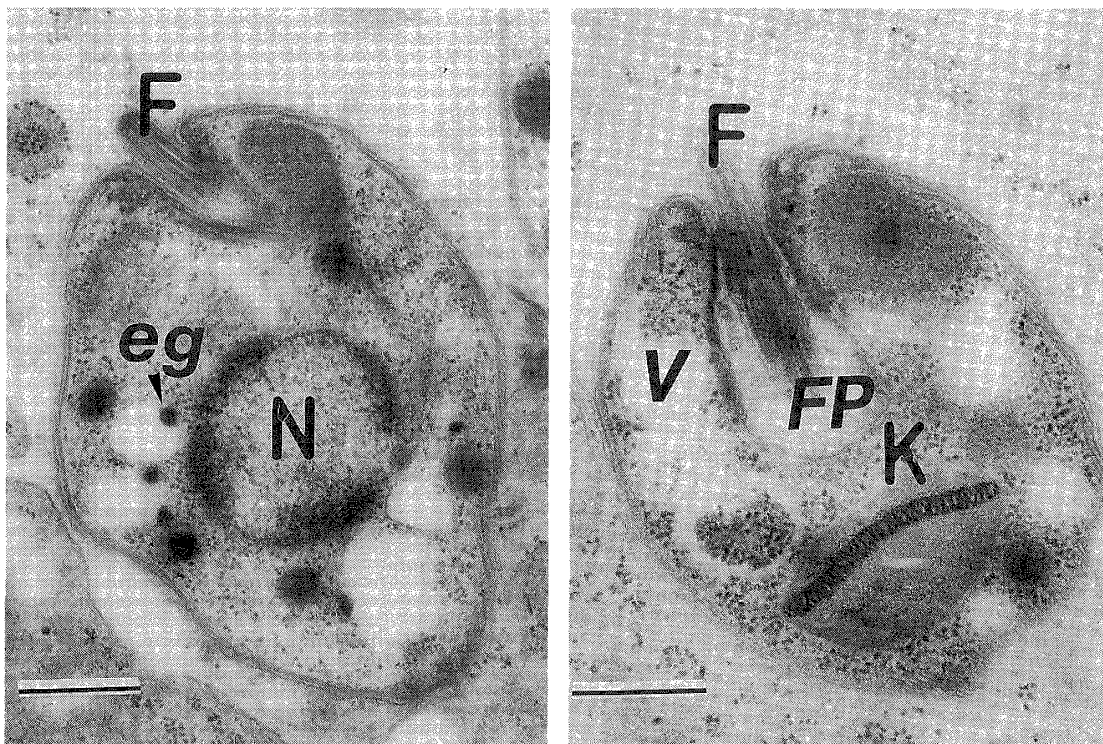


Figure 9 Ultrastructure of the *Leishmania* parasite. F=flagellum, N=nucleus, eg=electron dense granules inside the vacuole, FP=flagellar pocket, V=vacuole and K=kinetoplast. bar=500 nm.

parasitophorous vacuoles or outside the cell near the parasites. Specific lymphocytes were active in the specimens; some were in close contact with parasitized-macrophages (Fig. 4) and some were directly attached to the parasites (Fig. 5). Intracellular degeneration of parasites was observed inside the cytoplasm of the macrophages (Fig. 6). Degeneration of parasites was also noted inside the vacuole of macrophages that were almost destroyed by infections (Fig. 4). Parasites were also located in the cytoplasm of the eosinophils (Fig. 7) and neutrophils (Fig. 8) but no cellular vacuoles were seen in these cells. Almost similar changes were noted in the dermis of all three specimens.

3. Ultrastructure of amastigote:

The amastigotes seen were rounded or oval and of almost uniform size. The mean length was $2.62 \mu\text{m}$ (± 0.17 S.D.) and the mean width was $2.18 \mu\text{m}$ (± 0.28 S.D.). The amastigotes were surrounded by two layers of membranes and contained a rounded nucleus with a small nucleolus. The flagellum, flagellar pocket, kinetoplast, vacuoles and electron-dense granules could be distinguished (Fig. 9).

DISCUSSION

Various microscopic and histologic changes have been reported in the epidermis of lesions of cutaneous leishmaniasis, whether infected with New World or Old World *Leish-*

mania species (Zaar *et al.*, 1982; Grimaldi *et al.*, 1980). We observed amastigotes associated with lymphocytes and other mononuclear cells in spongiotic vesicles within the mid-epidermis. Mononuclear cells that may be macrophages, were seen in close contact with amastigotes. The close contact of these antigen-presenting cells with *Leishmania* suggests their capacity to recognize the parasite and facilitate its destruction. We also noted melanin granules in macrophages infected with more than one amastigote, again within the epidermis. The purpose of these melanin granules is unknown but leukocytes carrying similar bodies have been observed in the blood of healthy humans, reptiles and amphibians (Wasserman, 1965), melanin-containing macrophages are present within the epithelium of certain groups of fish. The histological studies of Kurban *et al.* (1966) revealed the presence of amastigotes in the prickle cell layer of 3 of 27 human cases, associated with intra-epidermal abscesses. Our findings suggest that, as in Old World species, New World *Leishmania* can infect the epidermis, and that keratinocytes appear to play an active part in cellular defence against the parasites.

Amastigote morphology was similar to that described for other *Leishmania* species, and no marked differences were discerned between biopsy material from patients with *L. guyanensis* (I-02) and *L. panamensis* (I-04) infections. We observed small, electron-dense granules and rounded or rod-shaped structures both inside parasitized vacuoles within the host macrophages and outside the cells. A similar finding was reported by Schurr *et al.* (1987), who considered that the granules originated either from the macrophage or the amastigotes. We suggest that they arise from the latter, because they occur regularly in the intracellular parasitized areas; their function is however unknown. Other intracellular bodies of undetermined function seen in *Leishmania* parasites including the lysosomes seen in *L. tropica* by Lin *et al.* (1986), liposomes containing a wax-like material noted by Scorza *et al.* (1979) in the amastigotes of *L. garnhami*, and the virus-like particles in *L. hertigi* were described by Molyneux (1974). None of these bodies were seen during the present study.

Various theories have been proposed to explain the fate of the parasite within the host cell. It is generally agreed that *Leishmania* is able to multiply and grow within the macrophage (Berman *et al.*, 1979), but there have been conflicting opinions about the role of the macrophage in killing the parasite intracellularly. By electron microscopic examination, Bretana *et al.* (1983) showed the macrophages are incapable of digesting the parasites. Farah *et al.* (1975) reported that parasites can only be destroyed on the surface of macrophages but not the inside of the cell. Our studies found the degeneration of parasites within the macrophage both either inside the vacuoles or free in the cytoplasm. This indicates the active role of macrophages in the intracellular destruction of parasites. Similar results have also been presented by the Sandbank (1976), who showed the degeneration of parasites within the macrophage in human specimens. Moreover, we observed the degeneration of parasites in the macrophage where the host cell was also undergoing degeneration. The degeneration of the host cell may be due to the parasitic load or attack or to some unknown factors of the cell itself. The conditions and mechanism of the intracellular destruction of parasites were not elucidated in the present study.

Lymphocytes were seen to be in close contact with parasitized macrophages. This macrophage-lymphocyte combination represents the cooperation of two cells against the parasites. Here the function of lymphocytes can be assumed to be: (1) to recognize the parasitized macrophage that may finally result in the destruction of host macrophage and

thereby liberate the parasite (Schurr *et al.*, 1987); (2) to help the macrophage kill the invading *Leishmania* (Mauel *et al.*, 1978), as shown in our results. On the basis of immunocytochemical and electron microscopic studies in animals, it has been suggested that T-cells provide lymphokines that can activate the host macrophage to destroy the parasites intracellularly or that T-cells play a cytotoxic role, killing the infected macrophages and helping to destroy the liberated extracellular parasites (McElrath *et al.*, 1987). Interestingly, mononuclear cells which were morphologically determined as lymphocytes, were attached to parasites, showing their capacity to attack the parasites directly, although, exact function and mechanism remain unknown. Lymphocytes attached to parasitized macrophages may be cytotoxic T-cells. During the present study degeneration of amastigotes was seen within host cells subjected to attack by the immune system, and from this finding we conclude that the parasites may be destroyed by the macrophage they have invaded, although the destruction mechanisms are unknown. Observation of amastigotes inside the cytoplasm of eosinophils and neutrophils suggest that they are phagocytized by these cells. Amastigotes have also been reported in the eosinophils of laboratory-infected BALB/c mice (Barral-Netto *et al.*, 1987; McElrath *et al.*, 1987).

Based on our findings in the present study, we suggest that macrophage serves to destroy the parasite intracellularly, and that lymphocytes (probably cytotoxic T-cells) have a major role in the immune response to *Leishmania* infection.

ACKNOWLEDGEMENTS

The authors are grateful to Professor and Director Hikotaro Yoshida, Department of Dermatology, Nagasaki University, for his valuable discussions.

REFERENCES

- 1) Armijos, R.X., Chico, M.D., Cruz, M.E., Guderian, R.H., Kreutzer, R.D., Berman, J.D., Rogers, M.D. and Grogil, M. (1990): Human cutaneous leishmaniasis in Ecuador: Identification of parasites by enzyme electrophoresis, *Am. J. Trop. Med. Hyg.*, 42, 424-428
- 2) Berman, J.D., Dywer, D.M. and Wyler, D.J. (1979): Multiplication of *Leishmania* in human macrophages *in vitro*, *Infect. Immun.*, 26, 375-379
- 3) Bretana, A., Avila, J.L., Lizardo, G., Convit, J. and Rondon, A.J. (1983): *Leishmania* species: Comparative ultrastructure of experimental nodules and diffuse human cutaneous lesions in American leishmaniasis, *Exp. Parasitol.*, 55, 377-385
- 4) Barral-Netto, M., de Fteitas, L.A.R. and Andrade, Z.A. (1987): Histopathological changes induced by vaccination in experimental cutaneous leishmaniasis of BALB/c mice, *Am. J. Pathol.*, 127, 271-278
- 5) Farah, F.S., Samra, S.A. and Nuwari-Salti, N. (1975): The role of macrophage in cutaneous leishmaniasis, *Immunology*, 29, 755-764
- 6) Grimaldi, G.Jr., Moriearty, P.L. and Hoff, R. (1980): *Leishmania mexicana*: Immunology and histopathology in C3H mice, *Exp. Parasitol.*, 50, 45-56
- 7) Hashiguchi, Y. and Gomez, E.A.L. (1990): A general situation of leishmaniasis and its endemic region in Ecuador. Studies on New World leishmaniasis and its transmission, with particular reference to Ecuador. Research Report Series No. 2, 6-18
- 8) Hashiguchi, Y., Gomez, E.A.L., Coronel, V.V., Mimori, T., Kawabata, M., Furuya, M., Nonaka,

- S., Takaoka, H., Alexander, B., Quizhpe, A.M., Grimaldi, G.Jr., Kreutzer, R.D. and Tesh, R.B. (1991): Andean leishmaniasis in Ecuador caused by infection with *Leishmania mexicana* and *L. major*-like parasites, *Am. J. Trop. Med. Hyg.*, 44, 205-217
- 9) Kurban, A.K., Malak, J.A., Farah, F.S. and Chaglassian, H.T. (1966): Histopathology of cutaneous leishmaniasis, *Arch. Derm.*, 93, 396-401
 - 10) Lainson, R. and Shaw, J.J. (1987): Evolution, classification and geographical distribution. Peters, W., Killick-Kendrick, R. (eds.) *The Leishmaniasis in Biology and Medicine, Biology and Epidemiology*. Vol. 1, 1-120 London: Academic Press,
 - 11) Lin, C-S., Wang, W-J., Wong, C-K. and Chao, D. (1986): Cutaneous leishmaniasis. Clinical, histopathological and electron microscopic studies, *Int. J. Dermatol.*, 25, 511-515
 - 12) Molyneux, D.H. (1974): Virus-like particles in *Leishmania* parasites, *Nature.*, 249, 588-589
 - 13) Mael, J., Buchmuller, Y. and Behin, R. (1978): Studies on the mechanisms of macrophage activation. I. Destruction of intracellular *Leishmania enriettii* in macrophages activated by cocultivation with stimulated lymphocytes, *J. Exp. Med.*, 148, 393-407
 - 14) McElrath, M.J., Kaplan, G., Nusrat, A. and Cohn, Z.A. (1987): Cutaneous leishmaniasis. The defect in T cell influx in BALB/c mice, *J. Exp. Med.*, 165, 546-559
 - 15) Mimori, T., Grimaldi, G.Jr., Kreutzer, R.D., Gomez, E.A.L., McMahon-Pratt, D., Tesh, R.B. and Hashiguchi, Y. (1989): Identification, using isoenzyme electrophoresis and monoclonal antibodies, of *Leishmania* isolated from humans and wild animals of Ecuador, *Am. J. Trop. Med. Hyg.*, 40, 154-158
 - 16) Nonaka, S., Gomez, E.A.L. and Hashiguchi, Y. (1990a): A comparative study of cutaneous changes of leishmaniasis patients from high land and low land in Ecuador. Hashiguchi Y., (ed.) *Studies on New World leishmaniasis and its transmission, with particular reference to Ecuador*, Research Report Series No. 2, Kochi, Japan: Kyowa Printing Co., 150-162
 - 17) Nonaka, S., Gomez, E.A.L. and Hashiguchi, Y. (1990b): Dermatological and histopathological examinations of leishmaniasis in Ecuador. Hashiguchi Y., (ed.) *Studies on New World leishmaniasis and its transmission, with particular reference to Ecuador*, Research Report Series No. 2, Kochi, Japan., 163-184
 - 18) Pearson, R.D. and Sousa, A.D.Q. (1985): *Leishmania* species: visceral (kala-azar), cutaneous and mucosal leishmaniasis, *Principles and practice of infectious diseases*, (3rd ed.) Ed. by Mandell, G.L. *et al.*, Churchill Livingstone (New York), 2066-2077
 - 19) Sandbank, M. (1976): Cutaneous leishmaniasis. Ultrastructural study of 3 cases, *Arch. Derm. Res.*, 257, 195-201
 - 20) Scorza, J.V., Valera, M., Scorza, C.D., Carnevali, M., Moreno, E. and Lugo-Hernandez, A. (1979): A new species of *Leishmania* parasite from the Venezuelan Andes region, *Trans. R. Soc. Trop. Med. Hyg.*, 73, 293-299
 - 21) Schurr, E., Wunderlich, F. and Tadesse, G. (1987): Electron microscopical studies on cutaneous leishmaniasis in Ethiopia. II. parasite and host cell differences between the localized and the diffuse form, *Acta. Tropica.*, 44, 395-407
 - 22) Wassermann, H.H. (1965): Leukocytes and melanin pigmentation. Demonstration of pigmented leukocytes in blood of amphibians, reptiles and normal man, *J. Invest. Dermatol.*, 45, 104-109
 - 23) Zaar, K., Wunderlich, F. and Beheh, A. (1982): Electron microscopical studies on cutaneous leishmaniasis in Ethiopia. I. The diffuse form and its treatment with pentamidine, *Ann. Trop. Med. Parasitol.*, 76, 595-605

エクアドル共和国における皮膚リーシュマニア症の電顕的検討

A.M. BHUTTO¹・岡田 茂¹・野中 薫雄¹・
E.A. Gomez L.²・橋口 義久³

エクアドル共和国で、3例の皮膚リーシュマニア症患者皮膚病変について、電顕的検討を行った。リーシュマニア虫体は真皮および表皮内に存在し、細胞内外に見られた。細胞質内の虫体の存在する部位には、空胞 (parasitophorus vacuoles) が見られたが、空胞がない状態でも虫体は観察された。Amastigotes は円形ないし卵円形で、その平均直径は、長径 $2.62\text{ }\mu\text{m}$ (± 0.17 S.D.), 短径 $2.18\text{ }\mu\text{m}$ (± 0.28 S.D.) であった。虫体は貪食細胞の細胞質内あるいは空胞内で、変性像を示しているものが見られた。それらの貪食細胞の付近では、リンパ球が虫体と直接接触した像や、虫体を有する貪食細胞と密接に接したりする像が見られた。さらに表皮内に海綿状小水疱が観察されたが、その部では虫体が確認され、同時にリンパ球や単核球の浸潤が確認された。虫体は表皮細胞内外にも観察され、同様に単核球との接着が見られた。単核球内にはメラニン顆粒が観察され、それらの細胞質内にも虫体が見られた。その他好酸球や多核球の一部にも、細胞質内に虫体が見られた。

電顕的観察により、リーシュマニア虫体は、真皮のみならず表皮にも存在することが確認された。これらの虫体、あるいは貪食細胞に対して、リンパ球が密接に接着し、なんらかの免疫反応を起こしているものと示唆された。以上の点から、虫体と貪食細胞の関係、虫体に対するT細胞の役割、貪食細胞内の虫体の死滅について文献的検討を行った。

1 長崎大学医学部皮膚科学教室

2 Departamento de Medicina Tropical, Facultad de Medicina, Universidad Catolica, Santiago de Guayaquil, Ecuador

3 高知医科大学寄生虫学教室