

Case report

# CASE REPORT OF LEPROSY AND A TRIAL OF SCREENINGS FOR THE FAMILY MEMBERS IN ECUADOR

ATSUSHI HOSOKAWA, SHIGEO NONAKA, JUAN J. ALAVA P,  
EDUARDO A. GOMEZ L., HUGO M. JURADO S  
AND YOSHIHISA HASHIGUCHI

Received September 20, 1994/ Accepted October 25, 1994

**Abstract:** Four cases of patients with leprosy were seen in an area endemic for cutaneous leishmaniasis, Los Ranchos, Department of Manabi, Ecuador. Two cases of them (borderline lepromatous leprosy and indeterminate one) in a single family and result of screenings for the family members were reported. It was suggested that family examination of leprosy patient might be useful for early detection of leprosy in a low endemic areas for leprosy, such as Department of Manabi. A nine banded armadillo kept by the family was examined, but no acid-fast bacilli was observed in the liver materials.

### INTRODUCTION

Leprosy and leishmaniasis are etiologically completely different diseases but it has been known that the two diseases have similar cutaneous manifestations (Jopling, 1984; Butto *et al.*, 1994). Therefore, both diseases should be differentiated in the endemic areas. During a survey for cutaneous leishmaniasis in Ecuador,

leprosy patients were also examined. The current paper deals with the two cases in a single family in detail and preliminary screenings for the family members of leprosy. Furthermore, based on the result obtained a brief comment was also made on the screening methods to detect leprosy patients in early stage of the disease.

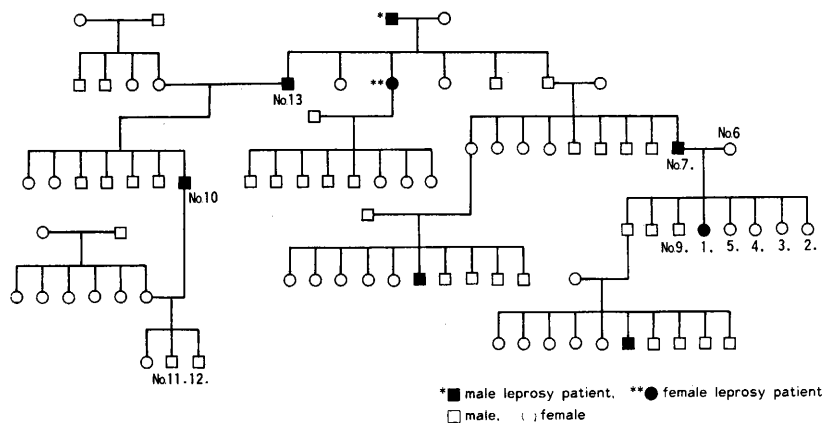


Figure 1 The pedigree of leprosy patients in Los Ranchos, Department of Manabi, Ecuador.

1. Department of Dermatology, Faculty of Medicine, University of the Ryukyus, Nishihara, Okinawa 903-01, Japan
2. Universidad Tecnica de Portoviejo, Portoviejo, Manabi, Ecuador.
3. Departamento de Medicina Tropical, Facultad de Medicina, Universidad Catolica Santiago de Guayaquil, Guayaquil, Ecuador
4. Centro Nacional de Medicina Tropical, Facultad de Ciencias Medicas, Universidad de Guayaquil, Guayaquil, Ecuador
5. Department of Parasitology, Kochi Medical School, Nankoku, Kochi 783, Japan

**CASE 1**

The patient was a 41-year-old-male (No-7).

**Family history.** His grand father, an uncle, an aunt, a nephew, a cousin, and a daughter were reported as suffering from leprosy by interview to the family (Fig. 1).

**Present history.** About 15 years ago, erythemata with anesthesia appeared on the abdomen. The eruption gradually increased in number on the face, the trunk and the four extremities. At the same time, there was a rising in body temperature, and neuralgia appeared in both extremities. In 1982, a doctor from the Welfare Ministry diagnosed him as leprosy.

**Treatment.** A 100mg per day of DDS (4, 4'-diaminodiphenylsulfone) was regularly prescribed for two years. In 1990, multidrug therapy (MDT) was started according to MDT for multi-bacillary leprosy recommended by the World Health Organization (WHO) (Noodeen, 1991). His prescription was as follows; DDS (100mg/day) and B-663 (50mg/day), every day; B-663 (300mg/day) and Rifampicin (600mg/day), once a month.

**Present illness.** Infiltrated erythemata on the face, destruction of nasal septum and deformity of the nose were observed (Fig. 2). Pea sized reddish nodules on the earlobes were soft and the induration of the lesions were

not palpated (Fig. 3). Annular and infiltrated erythemata were scattered on the trunk. Anesthesia was observed on all these eruptions. The body surface was dry except for the axillary, the epigastric, the lower abdomen, the inguinal, the perineal and the anal region. The ichthyosis-like change was seen on the region of the waist, the back, the extensor aspect of the legs and the feet (Fig. 4). Although the deep ulcers on the soles had the sharply demarcated bank, it did not have the induration at the margin of the ulcer that was observed in cutaneous leishmaniasis. The patient had anesthesia at the ulcers and could walk without pain. The big toes were mutilated and remaining toes were shortened (Fig. 5). Bilateral apehands and claw-hands were seen and fissures caused by trauma on the right palm were marked (Fig. 6). There was no loss of hair at any region of the body. Hypertrophy of the ulnar nerves were palpated at the elbows.

**Laboratory examination.**

1) The lepromin test: negative.

2) Value of anti-phenolic glycolipid (PGL)-I and anti-lipoarabinomannan (LAM)-B antibody: Positive result were PGL-I (IgG) 0.089 OD unit, PGL-I (IgM) 1.693 OD unit, LAM-B (IgG) 0.545 OD unit and LAM-B (IgM) 0.281 OD unit.

3) Examination of sensory function: Anesthesia

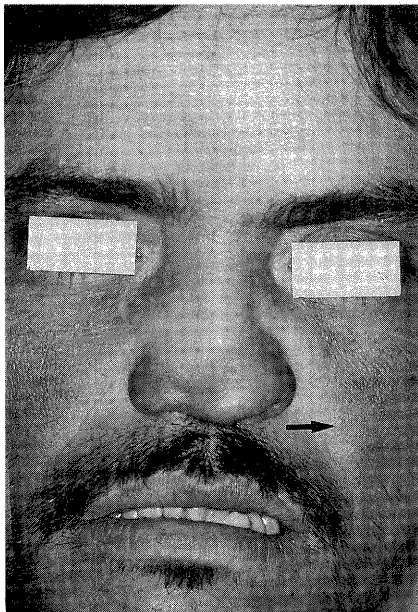


Figure 2 Deformity of the nose because of destruction of nasal septum and infiltrated erythema with sensory loss on the face (→) of Case 1 (No. 7: 41-year-old male).

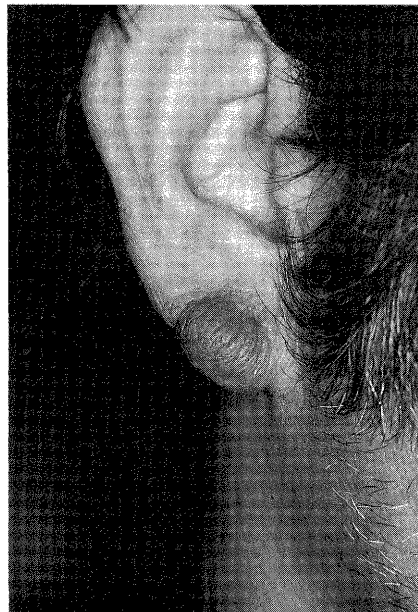


Figure 3 Pea sized nodule with sensory loss on the earlobe of Case 1.

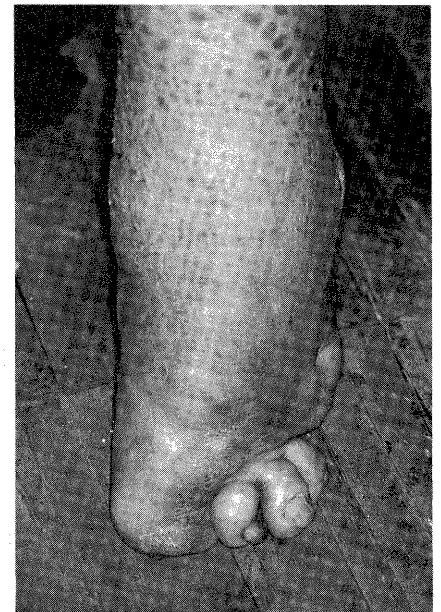

Figure 4 The ichthyosis-like change on the extensor aspect of leg and foot. Deformity of toes are also observed.

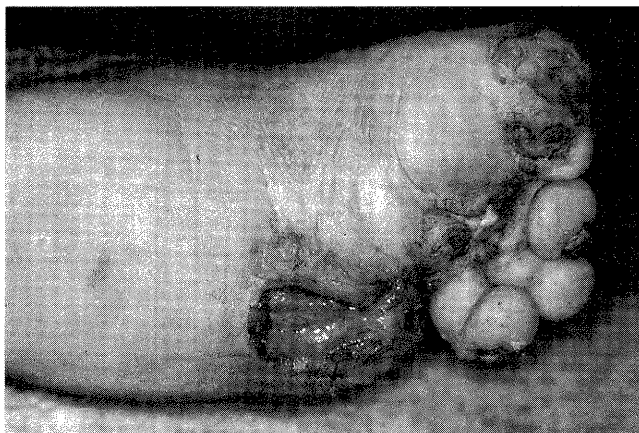


Figure 5 Deep ulcer on the sole and shortened and mutilated toes on the foot of Case 1.

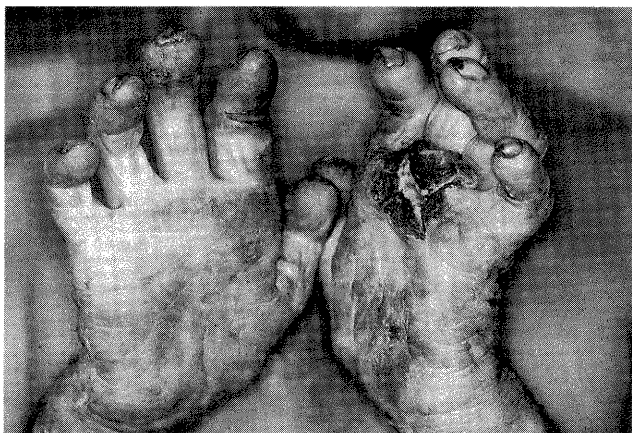

Figure 6 Ape-hand and claw-hand of both hands of Case 1.

was observed on all over the body surface except for the scalp, the axillary, the epigastric, the inguinal, the perineal and the anal region.

4) Histological findings of the specimen taken from the infiltrated erythema on the cheek: Rete peg disappeared. Clear subepidermal zone was observed (Fig. 7). Dermis was edematous. Though relatively large number of epithelioid cells and lymphocytes infiltrated in the dermis, epithelioid cell granuloma was not observed. By acid-fast staining (The Fite-Feraco staining Method), acid fast bacilli were observed (Fig. 8). Biopsy index: 3+, SFG index, 5; SFG value, 1-2-1. By skin slit smear of the left earlobe, acid fast bacilli stained by Ziehl-Neelsen's staining were found. Bacterial index showed 3+; SFG index, 4; and SFG value, 1-2-2. Nasal scraping was negative. The type of leprosy was borderline lepromatous.

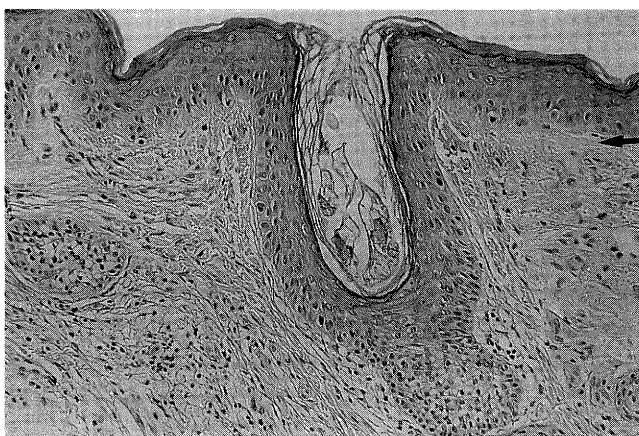


Figure 7 Case 1, clear subepidermal zone is presented (—→), and typical epithelioid cell granuloma is not presented (HE,  $\times 100$ ).

#### CASE 2

The patient was a 12-year-old female (No-1). A daughter of Case 1 (Fig. 1).

Present history. When we examined the family of the Case 1 patient, hypopigmented fleckle on the extensor aspect of the left thigh was noticed. The patient had been living in the house at the village of Los Ranchos, Department of Manabi since her birth.

Present illness. Palm sized hypopigmented freckle with anesthesia on the extensor aspect of the left thigh (Fig. 9). Hair loss was not observed at any region of the body surface. Hypertrophy of peripheral nerve was not palpated.

Laboratory examination;

1) Mitsuda early reaction (48 hrs): 7.5mm  $\times$  7.5mm/7.5mm  $\times$  7.5mm, undeterminable (+/-).

2) Value of anti-PGL-I and LAM-B antibodies: Positive results were PGL-I (IgG) 0.117 OD unit, PGL-I (IgM) 0.804 OD unit and LAM-B (IgM) 0.191 OD

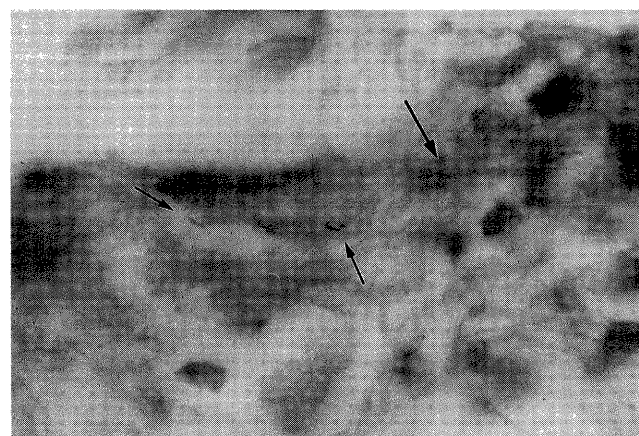


Figure 8 Case 1, *Mycobacterium leprae* (—→) observed in dermis (Fite-Feraco staining Method,  $\times 1,000$ ).

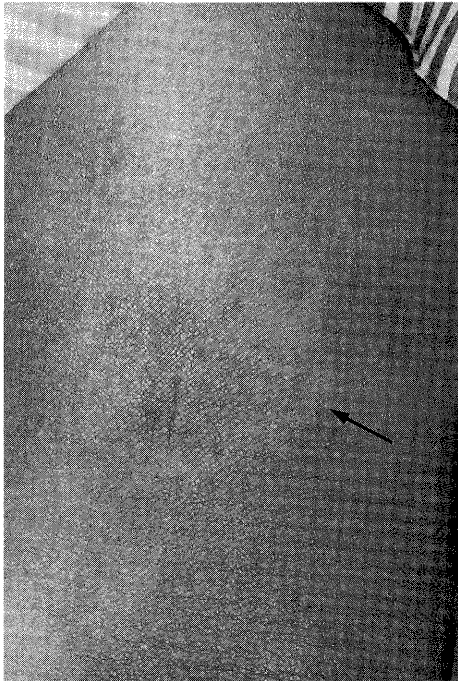


Figure 9 Palm sized hypopigmented freckle with anesthesia on the extensor aspect of thigh of Case 2 (→).

unit. Negative result was LAM-B (IgG) 0.060 OD unit.

3) Examination of sensory function: Anesthesia was observed only at the lesion of the left thigh.

4) Histological findings of the specimen taken from the lesion; small number of lymphocytes infiltrate around the capillaries and the appendages. There was no epithelioid cell granuloma in the dermis. No acid fast bacilli was observed in the skin tissue section stained by acid-fast staining (Ziehl-Neelsen and the Fite-Feraco staining Methods). The patient was diagnosed as indeterminate leprosy according to the histological and clinical criteria of Ridley and Jopling (1966).

Besides the two cases mentioned above, other two leprosy patients (one with borderline tuberculoid and other with unknown type) were examined in the current study. In addition to these four cases, the existence of other four patients with leprosy in this village was determined. Based on these examinations and interview, the figure of the pedigree was depicted, including relationships among leprosy patients in the endemic area for cutaneous leishmaniasis of Los Ranchos, Department of Manabi (Fig. 1). A nine banded armadillo kept by the family was examined, but no acid-fast bacilli was observed in the liver materials.

Comments;

Leprosy (Hansen's disease) is a chronic

mycobacterial disease (infectious in some cases), primarily affecting the peripheral nervous system and secondarily involving skin and certain other tissues (Jopling, 1984). Leprosy has a wide range distribution in the world. Leprosy is included among the six most important infectious diseases, as well as leishmaniasis, which the WHO planned to stop from being an endemic, and is still a public health problem in developing countries including Ecuador. In Ecuador, 110 patients with leprosy were newly diagnosed in 1991; the prevalence rate of leprosy in Ecuador was relatively low (0.25 per 1,000 habitants in total) in comparison with that of endemic areas such as South east Asia and Africa, 0.1-4.9 and 0.1-6.9 per 1,000 hab. respectively (McDougall *et al.*, 1989). It was relatively low (0.10-0.16 per 1,000 hab.) in Department of Manabi, from where the present cases were reported. As to future group examinations for leprosy, in a low endemic area, such as Department of Manabi, the screening of leprosy family would be effective and useful in consideration of a program for the early detection. The deformities of Case 1 could be prevented by early detection and adequate treatment. Case 2 was fortunately detected in early stage of the disease by a doctor during the present examination.

In Okinawa, Japan, for example, group leprosy examinations had been done in almost all regions of the prefecture during about 20 years by specialists who were appointed by the prefectural governer (Saikawa, 1989). The examination was called as a general medical check-up and not as a mass examination for leprosy, because in Okinawa, many of the inhabitants have been prejudiced against leprosy patients as well as the inhabitants in Ecuador. Members of the group examinations were consisted of a leprologist, public health nurse from the public health center of each district, manager of leprosy and tuberculosis from the prefectural office, a dermatologist, an internist and a clinical technologist etc. In the group examination, therefore, various examinations were done to find skin diseases, infectious diseases including leprosy and tuberculosis, circulatory diseases such as hypertension, diabetes mellitus and other internal disorders. The data from this medical check-up were reported to each subject by the public health center. If some pathological result was observed, the subjects were examined in detail at the nearest hospital or public health center. Leprosy patients detected in the general medical check-up were treated by the leprologists. Their family members were also examined in detail and some of them received preventive medication.

Recently, serodiagnosis of leprosy was considered

as one of the useful methods for early diagnosis (Buchanan, *et al.*, 1983). The serodiagnosis have also been carried out by leprologists in Okinawa (Abe *et al.*, 1991). During the current family examination, serological examination for 13 subjects was also carried out. Three leprosy patients were positive for PGL- I (IgM) and LAM-B (IgG), and three out of four leprosy patients were strongly positive for LAM-B (IgM) (data not shown). Based on the results, it was suggested that serological examination of families of leprosy might be useful for screening of house hold contacts in a low endemic area for leprosy.

These systems of group leprosy examination in Okinawa might be a good guide for a future program for the early detection in Ecuador. In consideration of economical and man-power resources, some modifications will be needed to implement this system of group leprosy examination into Ecuador.

Cutaneous manifestations in leprosy sometimes showed a similarity to those of cutaneous leishmaniasis. Early nodular lesions of cutaneous leishmaniasis are similar to those of lepromatous leprosy (LL) and the type of cutaneous leishmaniasis most likely to be confused with LL is the disseminated anergic form. In post kala azar dermal leishmaniasis, hypopigmented fleckle appear on trunk and limbs, which should be distinguished from those observed in indetermined leprosy (Jopling, 1984). In the present preliminary examination for leprosy, anesthesia at the lesions was the most important symptom for the diagnosis.

The patients (Cases 1 and 2) kept a nine banded armadillo for their food. In the smear specimens of the liver, no acid-fast bacilli and *Leishmania* amastigotes were observed. Wild armadillo with leprosy were found in U. S. (Smith *et al.*, 1978; Marchiondo *et al.*, 1980). Although no such a report was described in Ecuador, the examination should be continued to ascertain whether leprosy was a zoonosis or not, and whether the nine banded armadillos were natural reservoirs of the pathogen in Ecuador.

## REFERENCES

- 1) Abe, M., Ozawa, T., Minagawa, F. and Yoshimoto, Y. (1991): Immunoepidemiological studies on subclinical infection in leprosy, *Jap. J. Leprosy*, 60, 72-84
- 2) Buchanan, T., Dissanyake, S., Young, D. B., Miller, R. A., Acedo, J. R., Harish, J. P., Khanolka, S. R. and Estrada-Parra, S. (1983): Evaluation of significance of antibodies to phenolic glycolipid of *Mycobacterium leprae* in leprosy patients and their contacts, *Int. J. Lepr.*, 51, 658-659
- 3) Butto, A. M., Nonaka, S. and Hashiguchi, Y. (1994): First case of diffuse cutaneous leishmaniasis in Ecuador, *Jpn. J. Trop. Med. Hyg.*, 22 (supplement), 97
- 3) McDougall, A. C. and Yawalkar, S. J. (1989): Distribution of leprosy, *Leprosy*, second ed., 11, CIBA-EIGY LTD, Basel
- 4) Jopling, W. H. (1984): Definition, Epidemiology and World Distribution, *Handbook of leprosy*, third ed., 1, William Heineman Medical Book LTD, London
- 5) Jopling, W. H. (1984): Differential diagnosis. *Handbook of leprosy*, third ed., 121, William Heineman Medical Book LTD, London
- 6) Kosaka, K., Yoneda, K., Makiko, M., Mori, T. and Itoh, T. (1978): Nude mouse for research in leprosy, *Int. Lepr. Congr. Proc.* XI, 37-43
- 7) Marchiondo, A. A., Smith, J. H. and File, S. K. (1980): Naturally occurring leprosy-like disease of wild armadillos, ultrastructure of lepromatous lesions, *J. Reticuloendothel. Soc.*, 27, 311-325
- 8) Noordeen, S. K. (1991): Global review of MDT Implementation, *Wld. Hlth. Org. techn. rep. ser.*, 116
- 9) Ridley, D. S. and Jopling, W. H. (1966): Classification of Leprosy According to Immunity, *Int. J. Lepr.*, 34, 255-273
- 10) Saikawa, K. (1989): Epidemiology of leprosy. *Jap. J. Leprosy*, 58, 143-156
- 11) Sheperd, C. C. (1965): Stability of *M. leprae* and temperature optimum for growth, *Int. J. Lepr.*, 33, 541-547
- 12) Smith, J. H., File, S. K., Nagy, B. A., Folse, D. S., Buckner, J. A., Webb, L. J. and Beverding, A. M. (1978): Leprosy-like disease of wild armadillo in French Acadiana, Louisiana. *J. Reticuloendothel. Soc.*, 24, 705-719